

Case Report: Clinical Gynaecology and Breast

Post-Covid-19 Vaccine Inflammatory Reaction in Dermal Filler Injection Sites: A Case Report

Omid Etemad², Ali Yavari^{1*}, Changiz Delavari¹

¹ MD Department of plastic and reconstructive surgery, imam Khomeini hospital complex, medicine faculty, Tehran university of medical science, Tehran, Iran.

² Department of plastic and reconstructive surgery, zare burn hospital, medicine faculty, Mazandaran university of medical science, Sari, Iran.

Corresponding Author: Ali Yavari, Department of plastic and reconstructive surgery, zare burn hospital, medicine faculty, Mazandaran university of medical science, Sari, Iran.

Received Date: 29 November 2025 | **Accepted Date:** 10 December 2025 | **Published Date:** 22 December 2025

Citation: Omid Etemad, Ali Yavari, Changiz Delavari; (2025); Research Article: Post-Covid-19 Vaccine Inflammatory Reaction in Dermal Filler Injection Sites: A Case Report; Clinical Gynaecology and Breast 4(6); DOI: 10.31579/2834-8427/047

Copyright: © 2025 Ali Yavari, this is an open-access article distributed under the terms of the Creative Commons Attribution License, which permits unrestricted use, distribution, and reproduction in any medium, provided the original author and source are credited.

Abstract

After the declaration of COVID-19 as a pandemic, a race began for development of an effective vaccine. Like any other intervention, these vaccines were not risk free. One of the side effects previously discovered from the Moderna COVID-19 vaccine was swelling and pain following soft tissue filler injections. No similar report has never been published about the Sinopharm vaccine. Here we present a case of 25- year-old female who had lip filler injection at our clinic and after 8 weeks of waiting was injected with the Sinopharm vaccine, but had swelling, nodularity, and a burning sensation in her lips, regardless of the wait period, for whom oral steroids were prescribed and the side effects resolved.

Key words: adverse reaction; delayed reaction; type iv hypersensitivity; covid-19; sinopharm; lip filler

Introduction

In December 2019, a new strain of coronaviridae family emerged and the disease, COVID-19, was declared a pandemic by march 11, 2020. (1) Vaccines are considered to be one of the best ways for eradicating COVID-19, considering their risks and benefits. Several vaccines have been developed throughout the course of this pandemic, one of which is BBIBP-CorV vaccine, also known as the Sinopharm COVID-19 vaccine. (2) The Sinopharm vaccine is injected in two doses with 14 or 21 days of interval in between them (3). The Moderna vaccine has been previously shown to induce adverse effects on people with soft tissue filler injections (4), although, to this day, no previous reports of a similar reaction for the Sinopharm COVID-19 vaccine are available.

Here we present the first case of lip swelling, previously injected with filler, following the Sinopharm COVID-19 vaccine.

Case Presentation

A 25-year-old female attended our clinic for a lip augmentation procedure. The patient had no past medical history, drug history, allergic history, or any remarkable family history. (fig.1) 1cc Perfectha Deep lip filler was injected for this patient. (fig. 2) 2 months after the injection, the patient decided to apply for the Sinopharm COVID-19 vaccine. Prior to the injection, the patient had no adverse reaction to the filler. (fig. 3) 24 hours following the COVID- 19 vaccine, the patient showed signs of swelling in her lips with nodularities and a burning sensation at the site of lip injection. (fig. 4) The patient attended our clinic seeking help for the condition.

The patient underwent 7 days of cetirizine (10 mg, every 12 hours) with minimal to no improvement in her condition. After these 7 days, we started 25 mg of prednisolone (0.5mg/kg) per day (10 mg first dose, then 5mg every 8 hours for two days), for this patient. After the first dose, the patient showed remarkable signs of improvement, so we reduced the dose to 15 mg per day for another 24 hours and the swelling, nodularity, and the sensation of burning completely subsided. (fig. 5)

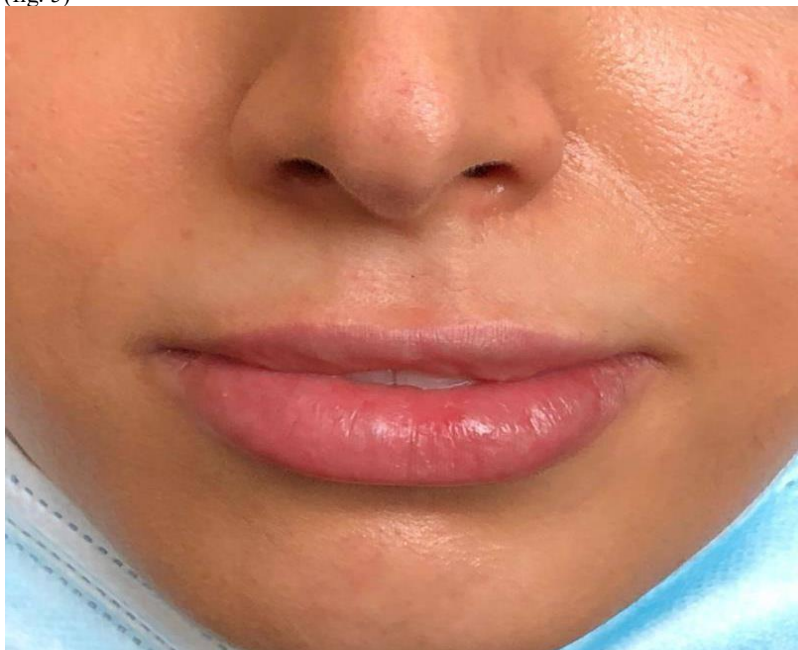

Figure. 1: Before filler injection

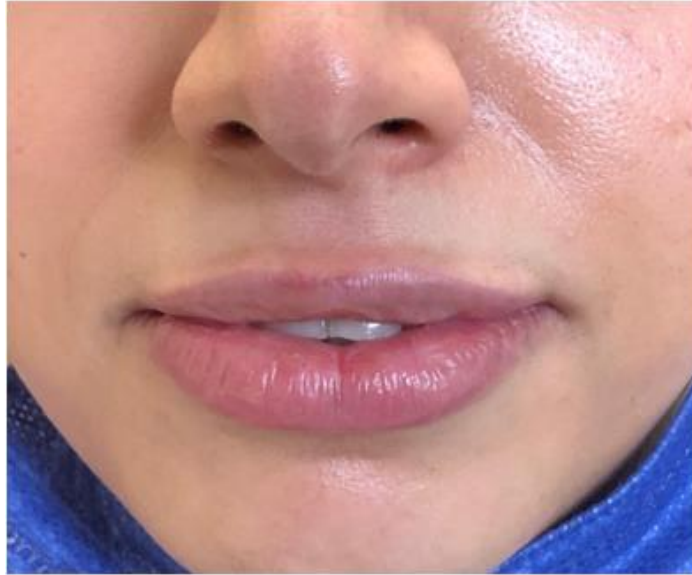

Figure. 2: After filler injection

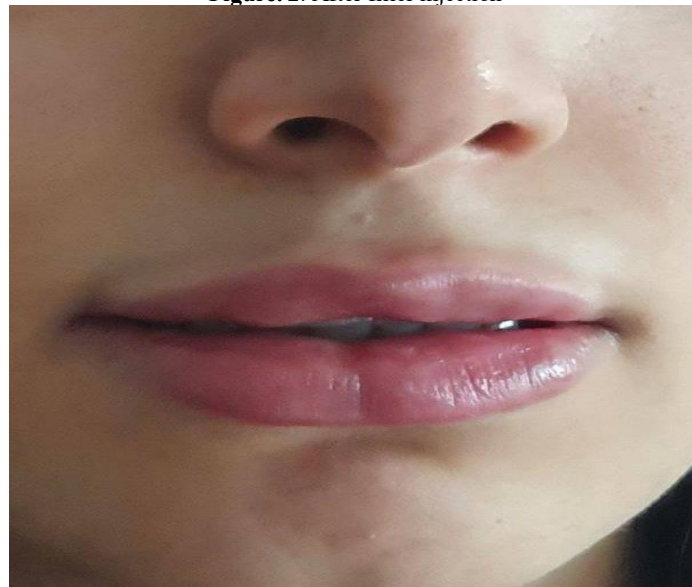


Figure. 3: 8 weeks after filler injection and before vaccine injection

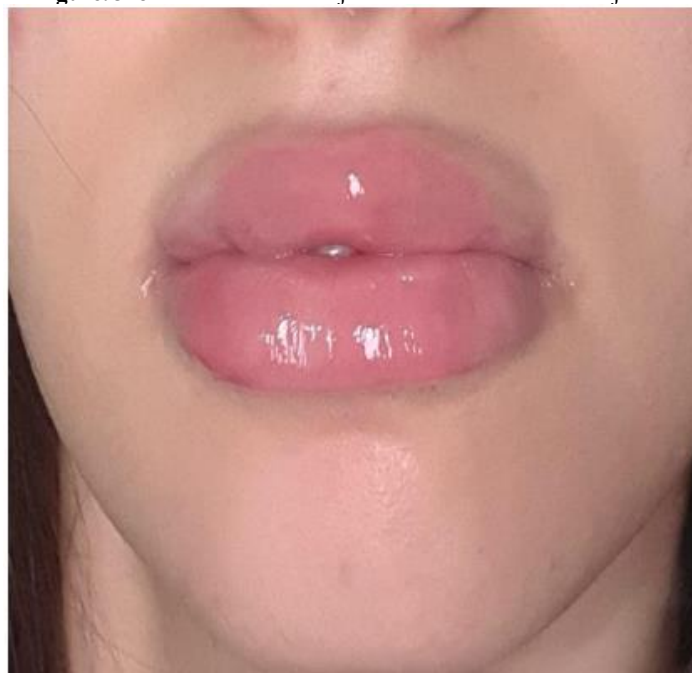

Figure 4: 24 hours after vaccine injection

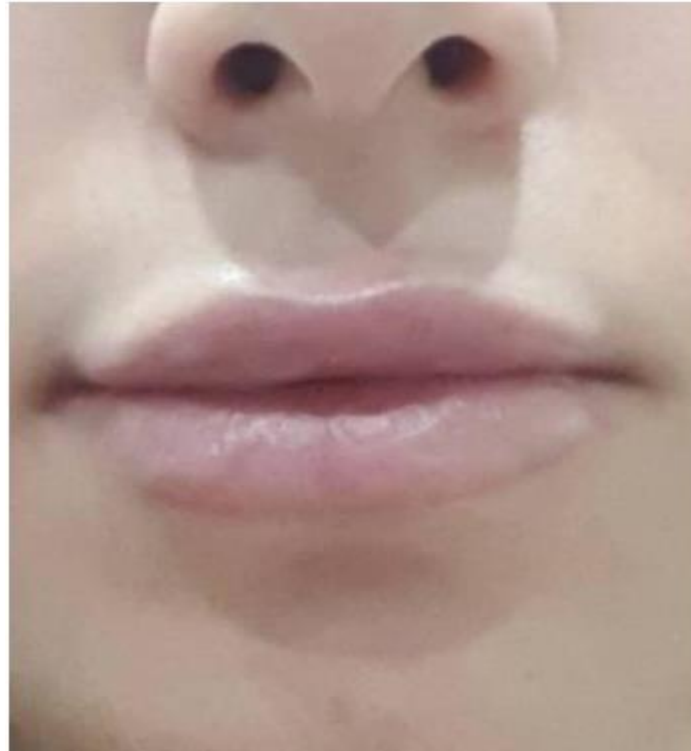


Fig. 5: 48 hours after corticosteroid therapy

Results

Considering the normal appearance of the patient after the lip injection and before the vaccine administration, we believe that there is a chance the Sinopharm vaccine could induce hypersensitivity for the patients who have had soft tissue filler injections in the 2-month period prior to the vaccine injection.

Discussion

Starting November 11, 2020, vaccines for COVID-19 began to be developed. Different countries and companies strived for a better, more efficient vaccine than their counterpart. (5) With any new treatment or prevention method, comes different hurdles and challenges to be overcome. One of the aforementioned obstacles is side effects. Vaccines are no exception. To prevent the disease, one might introduce dead antigens of the virus to the body to induce an immunological reaction, in case of the Sinopharm COVID-19 vaccine, aiming to prevent the disease from happening. (3) In this process, different individuals may or may not develop symptoms, suggestive of side effects of the vaccine.

In December 2020, a nucleoside modified mRNA vaccine called the Moderna COVID-19 vaccine was authorized for emergency use. (6) A global survey has been done. In the past it has been shown that the Moderna COVID-19 vaccine might induce adverse effects for patients who had previously undergone soft tissue filler injections. Swelling and pain are two reported adverse effects following the aforementioned vaccine. (4) However, to this day, no report has been published anywhere suggesting adverse effects regarding the Sinopharm COVID-19 vaccine and soft tissue filler injections. For our patient, we recommended a 2-week wait period between the filler injection and the vaccine, since it has been previously understood that Moderna could potentially result in a cutaneous adverse reaction after 8 days (7), but the patient extended the wait to 8 weeks. However, to our surprise, swelling and nodularity accompanied by a burning sensation occurred 24 hours after the vaccine injection, which would make this reaction be classified as delayed hypersensitivity, also known as type IV hypersensitivity. As mentioned before, oral antihistamine was prescribed considering the hypersensitivity being the probable pathology. After 7 days, no remarkable improvement occurred so we had to introduce corticosteroids. Corticosteroids were not our first line of therapy considering the potential reduced effect of the vaccine. After 24 hours of oral corticosteroid consumption, the patient showed remarkable improvements.

Conclusion

Considering the experience discussed above, we believe that even after a 60-day period between soft tissue injections and injection of the first dose of the Sinopharm vaccine, hypersensitivity might occur. Physicians are recommended to explain the possible side effects of the aforementioned vaccine for their soft tissue injection patients and recommend a follow-up visit if any symptoms, such as swelling or burning sensation and nodularities occur. The authors of this article suggest at least a 60-day wait period between soft tissue filler injection and injection of the Sinopharm vaccine, regardless of it being the first of the second dose. If the reactions do occur, we recommend starting the treatment with an antihistamine and if no improvement was achieved, the physician is recommended to start corticosteroids for the patient. Hyaluronidase must be reserved as a final resort if the steroids fail.

Conflict Of Interest

The authors declare no conflict of interest.

Fundings

The authors of the present study have received no funding from any institutions.

Informed Consent

The patient consented to be discussed in the present study and for her pictures to be published.

References

1. Habas K, Nganwuchu C, Shahzad F, Gopalan R, Haque M, Rahman S, et al. Resolution of coronavirus disease 2019 (COVID-19). *Expert Rev Anti Infect Ther.* 2020;18(12):1201-11.
2. Zhang Y, Zeng G, Pan H, Li C, Hu Y, Chu K, et al. Safety, tolerability, and immunogenicity of an inactivated SARS-CoV-2 vaccine in healthy adults aged 18-59 years: a randomised, double-blind, placebo-controlled, phase 1/2 clinical trial. *Lancet Infect Dis.* 2021;21(2):181-92.
3. Xia S, Duan K, Zhang Y, Zhao D, Zhang H, Xie Z, et al. Effect of an Inactivated Vaccine Against SARS-CoV-2 on Safety and Immunogenicity Outcomes: Interim Analysis of 2 Randomized Clinical Trials. *JAMA.* 2020;324(10):951-60.

4. Gotkin RH, Gout U, Sattler S, Piansay-Soriano ME, Wanitphakdeedecha R, Ghannam S, et al. Global Recommendations on COVID-19 Vaccines and Soft Tissue Filler Reactions: A Survey-Based Investigation in Cooperation With the International Society for Dermatologic and Aesthetic Surgery (ISDS). *J Drugs Dermatol*. 2021;20(4):374-8.
5. Saeed BQ, Al-Shahrabi R, Alhaj SS, Alkokhardi ZM, Adrees AO. Side Effects and Perceptions Following Sinopharm COVID-19 Vaccination. *Int J Infect Dis*. 2021.
6. Oliver SE, Gargano JW, Marin M, Wallace M, Curran KG, Chamberland M, et al. The Advisory Committee on Immunization Practices' Interim Recommendation for Use of Moderna COVID-19 Vaccine - United States, December 2020. *MMWR Morb Mortal Wkly Rep*. 2021;69(5152):1653-6.
7. McMahon DE, Amerson E, Rosenbach M, Lipoff JB, Moustafa D, Tyagi A, et al. Cutaneous reactions reported after Moderna and Pfizer COVID-19 vaccination: A registry-based study of 414 cases. *J Am Acad Dermatol*. 2021;85(1):46-55.

