

A Rare Case Report of Para Testicular Rhabdomyosarcoma in an Elderly Man.

Ojas Vijayanand Potdar*, Darshan Rath, Amol Kamble, Shashank Sharma, Shashank Sharma, Ashish Chaubey, Siddhanth Srivastava, Ashay Patil, Omar Khan

Grant Medical College and J.J. group of hospitals, Mumbai.

*Corresponding Author: Ojas Vijayanand Potdar, Grant Medical College and J.J. group of hospitals, Mumbai.

Received Date: November 06, 2024; Accepted Date: November 21, 2024; Published Date: November 10, 2024

Citation: Ojas Vijayanand Potdar, Darshan Rath, Amol Kamble, Shashank Sharma, Shashank Sharma, et al, (2024), A Rare Case Report of Para Testicular Rhabdomyosarcoma in an Elderly Man, *Clinical Trials and Clinical Research*,3(4); DOI:10.31579/2834-5126/083

Copyright: © 2024 Ojas Vijayanand Potdar. this is an open access article distributed under the creative commons' attribution license, which permits unrestricted use, distribution, and reproduction in any medium, provided the original work is properly cited.

Abstract

Para testicular embryonal rhabdomyosarcoma (RMS) is a rare tumour arising from the mesenchymal tissues of the spermatic cord, epididymis, testis and testicular tunics. We present a rare case of a 67-year-old male diagnosed to have a left sided Para testicular rhabdomyosarcoma managed by surgical excision and followed by chemotherapy.

Keywords: neoplastic etiology; chemotherapy

Introduction

Para testicular embryonal rhabdomyosarcoma (RMS) is a rare tumour arising from the mesenchymal tissues of the spermatic cord, epididymis, testis and testicular tunics.

Rhabdomyosarcoma (RMS) is one of the most frequent soft tissue sarcomas. Para testicular RMS is rare and consists 7% of all RMS.¹ Para testicular RMS represents the most common non-germinal malignant tumour in this site.² Para testicular RMS can develop from mesenchymal elements of the spermatic cord, the epididymis and the testicular envelopes, resulting in development of a painless scrotal mass. The clinical presentation includes a short history of painless swelling of the scrotum in a child or a young adult. Embryonal RMS is the predominant histological subtype and has a good prognosis. ³ RMS is regarded as a highly malignant tumour with frequent recurrence. Spread of the tumour is mostly by lymphatics to the iliac and

para-aortic nodes, but hematogenous spread does occur, most commonly to the lungs and liver. ^{2,4} The efficacy of chemotherapy has diminished the role of surgery and radiotherapy following radical excision in early stages. The combined modalities of surgery, chemotherapy and radiation therapy have greatly improved the survival rate in Para testicular RMS without significant long-term complications. We present a rare case of a 67-year-old male diagnosed to have a left sided Para testicular rhabdomyosarcoma managed by surgical excision and followed by chemotherapy.

Case presentation:

A 67-year-old male presented with complaints of left sided inguinoscrotal swelling since last 2 months which has progressively increased in size over the last 2 months. (Figure-1)



Figure1: Clinical picture showing evidence of Left sided inguinal swelling.

Patient reports history of left sided orchidectomy which was done through a left scrotal incision at a local hospital in his village and the details of the histopathology report was not available. Patient was further evaluated using ultrasound of the inguinoscrotal region which revealed heterogeneously heterochronic lesion with minimal internal vascularity suggestive of neoplastic etiology. Blood workup included tumour markers which revealed marginally elevated LDH levels with normal alpha-fetoprotein and Beta-

HCG levels. The patient was further evaluated using Contrast enhanced Computerised Tomography of Abdomen and Pelvis which revealed well defined heterogeneously enhancing hypodense soft tissue lesion involving left spermatic cord from superficial inguinal ring to the scrotal sac suggestive of neoplastic etiology. In view of the imaging findings suggestive of neoplastic etiology, the patient underwent excision of the mass through inguinal incision followed by chemotherapy with vincristine plus dactinomycin and ifosfamide (VAI) (Figure-2)

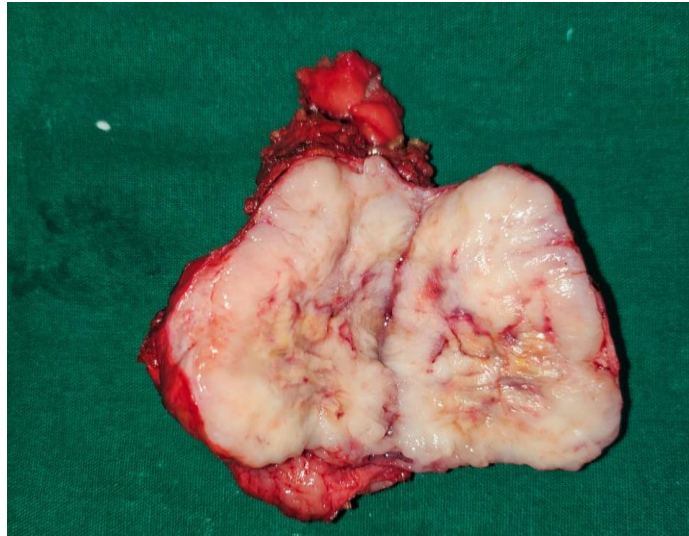


Figure2: Clinical picture of cut open resected specimen

The postoperative course was uneventful. The final histopathological examination revealed Para testicular rhabdomyosarcoma with margins free

of tumour with invasion of the surrounding tissue capsule with focal areas of perineural invasion. (Figure-3)

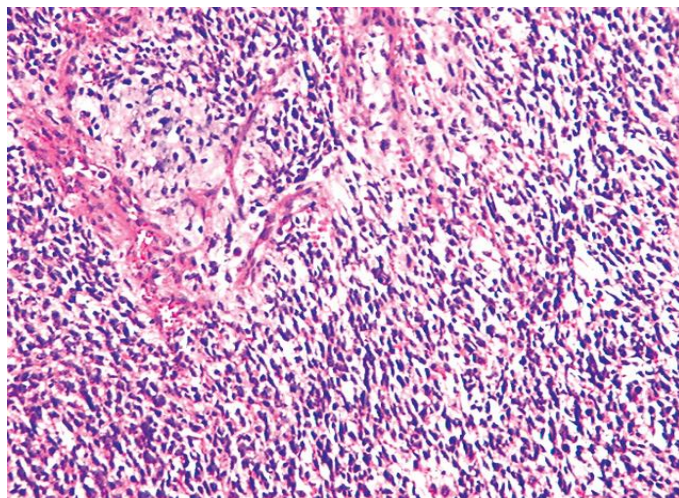


Figure3: Histopathological examination of the resected specimen showing evidence of Para testicular Rhabdomyosarcoma with invasion of the surrounding tissue sample with focal areas of perineural invasion.

The patient has been on regular 3 monthly follow-up with Imaging and tumour markers and clinical examination which has been normal.

Discussion:

The most common soft-tissue sarcoma of childhood is Rhabdomyosarcoma (RMS). Its incidence is similar in Africo-American and Caucasian and appears to be lower in Asian populations. There are two peaks in this histologic subtype of tumour, the first at the age of 4 years and the second at the age of 18 years.² However, this case report describes such an occurrence in a 67-year-old elderly male. Among all cases of rhabdomyosarcoma, approximately 7% occurs in paratestis. Clinically paratesticular tumour presents as a hard painless inguino-scrotal swelling.³ A hydrocele can be occasionally present in adults explaining the frequent mis diagnostic of

paratesticular rhabdomyosarcoma with hydrocele in this population. Regarding histologic features, embryonal RMS is predominant and represents 84% of all cases whereas alveolar and spindle cells are less frequent (8% and 5% respectively). The tumour spreads mostly by lymphatics to the iliac and para-aortic nodes, but hematogenous spread does occur most commonly to the lungs and liver.^{4,5} Work up investigations at diagnosis includes physical examination, chest x-ray, bilateral bone marrow smears and biopsies, abdominal and chest computed tomography (CT) scan, and bone scan.⁶ Staging of Para testicular rhabdomyosarcoma can be done according to both the tumour-nodes metastases classification and the Intergroup Rhabdomyosarcoma Study system.⁴ In the literature, patients are diagnosed at localized stages in 92% of the cases. Para testicular sarcomas are rare. There is no standard treatment. In the localized disease, treatment

strategies include radical high inguinal orchidectomy, retroperitoneal lymph node dissection, chemotherapy and radiotherapy.⁷⁻¹⁰ Some authors recommend ipsilateral nerve-sparing retroperitoneal lymph node dissection (RPLND) for all boys 10 years of age or older. This therapeutic approach is based upon results from the Intergroup Rhabdomyosarcoma Study IV which concluded that three-year PFS in boys over the age of 10 who had apparently localized paratesticular RMS but did not undergo routine RPLND was significantly worse than that of younger boys (68 versus 90 percent). Besides, the histologic confirmation of nodal metastases is helpful for decision making since patients with positive nodes are referred for postoperative RT as well as adjuvant chemotherapy. An alternative approach for patients with clinically enlarged retroperitoneal nodes is the administration of an adjuvant chemotherapy regimen (VAC or vincristine plus dactinomycin and ifosfamide (VAI)). The development of this adjuvant therapy has increased survival in patients with localized disease to approximately 60%.¹⁰ In the metastatic setting, many protocols of chemotherapy have been tried. VAC, IVA, and VIE protocols (V: vincristine, A: actinomycin, I: ifosfamide, E: etoposide, and C: cyclophosphamide) and better results were observed with VAC protocol.¹¹⁻¹³ In our series two cases received chemotherapy by MAI, and one patient was treated by VAC. The role of whole-lung RT (generally to 14.4 Gy) for patients with overt pulmonary metastases is not consensual; some protocols recommend it given the radiosensitivity of RMS. The prognosis of Para testicular rhabdomyosarcoma is extremely poor. Patients in the Intergroup Rhabdomyosarcoma Study IV had a 5-year survival rate of 22.2%. Furthermore, age seems to be a prognostic factor with a worse prognosis in adult patients than children (with a 5-year event-free survival and 5-year overall survival of 28% and 40%, respectively).⁴

Conclusion:

This case report highlights the case presentation and management of rare Para testicular rhabdomyosarcoma in an elderly male.

Acknowledgements:

I would like to thank all the staff at Grant Government Medical College, Mumbai for their co-operation and support.

Conflict of Interest:

There are no conflicts of interests

The authors have no relevant financial or non-financial interests to disclose.

The authors have no competing interests to declare that are relevant to the content of this article.

Funding Support:

Source of Funding: None

No funding was received to assist with the preparation of this manuscript.

Statement on ethical clearance and consent for participation:

Patient consent was obtained for publication of the case report.

Statement on Data availability:

It is a case report and data was obtained from the hospital records.

References:

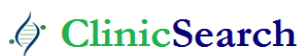1. Stewart LH, Lioe TF, Johnston SR. (1991). Thirty-year review of intrascrotal rhabdomyosarcoma. *Br J Urol* 68:418-420.
2. E Isässer E. (1997). Tumours of the epididymis. *Recent Results Cancer Res.* 163-175.
3. Ferrari A, Bisogno G, Casanova M, Meazza C, Piva L, et al. (2002). Paratesticular rhabdomyosarcoma: Report from the Italian and German Cooperative Group. *J Clin Oncol* 20:449-455.
4. Ferrari A, Casanova M, Massimino M, Luksch R, Piva L, et al. (1998). The management of Para testicular rhabdomyosarcoma: A single institutional experience with 44 consecutive children. *J Urol* 159:1031-1034.
5. Crist WM, Anderson JR, Meza JL, Fryer C, Raney RB, et al. (2001). Intergroup rhabdomyosarcoma study-IV: Results for patients with nonmetastatic disease. *J Clin Oncol* 19:3091-3102.
6. Eisenhauer EA, Therasse P, Bogaerts J, Schwartz LH, Sargent D, et al. (2009). new response evaluation criteria in solid tumours: Revised RECIST guideline (version 1.1). *Eur J Cancer* 45:228-247.
7. Kaplan EL, Meier P. (1958). Nonparametric Estimation from Incomplete Observations. *J Am Stat Assoc* 53:457-481.
8. Debruyne FM, Bökkenink JP, de Vries JD. (1985). Current concepts in the management of Para testicular rhabdomyosarcoma. *Eur Urol* 11:289-293.
9. Stewart RJ, Martelli H, Oberlin O, Rey A, Bouvet N, et al. (2003). Treatment of Children with Nonmetastatic Para testicular Rhabdomyosarcoma: Results of the Malignant Mesenchymal Tumours Studies (MMT 84 and MMT 89) of the International Society of Paediatric Oncology. *J Clin Oncol* 21:793-798.
10. Blyth B, Mandell J, Bauer SB, Colodny AH, Grier HE, et al. (1990). Para testicular rhabdomyosarcoma: Results of therapy in 18 cases. *J Urol* 144:1450-1453.
11. Khoubehi B, Mishra V, Ali M, Motiwala H, Karim O. (2002). Adult Para testicular tumours. *BJU Int* 90:707-715.
12. Hermans BP, Foster RS, Bihle R, Little S, Sandler A, et al. (1998). Is retroperitoneal lymph node dissection necessary for adult Para testicular rhabdomyosarcoma? *J Urol* 160 (6 Pt 1):2074-2077.
13. Crist W, Gehan EA, Ragab AH, Dickman PS, Donaldson SS, et al. (1995). The Third Intergroup Rhabdomyosarcoma Study. *J Clin Oncol* 13: 610-630.

Ready to submit your research? Choose ClinicSearch and benefit from:

- fast, convenient online submission
- rigorous peer review by experienced research in your field
- rapid publication on acceptance
- authors retain copyrights
- unique DOI for all articles
- immediate, unrestricted online access

At ClinicSearch, research is always in progress.

Learn more <http://clinicsearchonline.org/journals/clinical-trials-and-clinical-research>



© The Author(s) 2024. **Open Access** This article is licensed under a Creative Commons Attribution 4.0 International License, which permits use, sharing, adaptation, distribution and reproduction in any medium or format, as long as you give appropriate credit to the original author(s) and the source, provide a link to the Creative Commons licence, and indicate if changes were made. The images or other third party material in this article are included in the article's Creative Commons licence, unless indicated otherwise in a credit line to the material. If material is not included in the article's Creative Commons licence and your intended use is not permitted by statutory regulation or exceeds the permitted use, you will need to obtain permission directly from the copyright holder. To view a copy of this licence, visit <http://creativecommons.org/licenses/by/4.0/>. The Creative Commons Public Domain Dedication waiver (<http://creativecommons.org/publicdomain/zero/1.0/>) applies to the data made available in this article, unless otherwise stated in a credit line to the data.