

Wound healing and anti-inflammatory potential of *Ajuga bracteosa*- conjugated silver nanoparticles in Balb/c mice

Saiqa Andleeb ^{1*}, Sadia Nazer ¹, Suliman Yousef Alomar ², Naushad Ahmad ³, Imran Khan ⁴, Abida Raza ⁵, Uzma Azeem Awan ⁶, Sadaf Azad Raja ⁷

¹Microbial Biotechnology laboratory, Department of Zoology, University of Azad Jammu and Kashmir, Muzaffarabad, 13100, Pakistan.

²Zoology Department, College of Science, King Saud University, Riyadh-11451, Kingdom of Saudi Arabia.

³Department of Chemistry, College of Science, King Saud University, Riyadh-11451, Kingdom of Saudi Arabia.

⁴Acoustophoretic Single Embryo Characterization Laboratory (ASECL), Department of Biomedical Engineering, School of Medicine, Keimyung University 1095 Dalgubeol-daero, Dalseo-gu, Daegu, 42601, Korea.

⁵Department of Zoology, Government College University, Lahore, Pakistan.

⁶National Institute for Lasers and Optronics (NILOP), Pakistan Atomic Energy Commission, Islamabad, Pakistan

⁷Department of Biological Sciences, National University of Medical Sciences (NUMS), Rawalpindi, Pakistan 8Bioscience Department, COMSATS University, Park Road, Chak Shahzad, Islamabad, 44000, Pakistan.

***Corresponding Author:** Saiqa Andleeb, Microbial Biotechnology laboratory, Department of Zoology, University of Azad Jammu and Kashmir, Muzaffarabad, 13100, Pakistan.

Received date: June 28, 2024; **Accepted date:** April 19, 2024; **Published date:** April 26, 2024

Citation: Saiqa Andleeb, Sadia Nazer, Suliman Yousef Alomar, Naushad Ahmad, Imran Khan, Abida Raza, Uzma Azeem Awan, Sadaf Azad Raja, (2024). Wound healing and anti-inflammatory potential of *Ajuga bracteosa*- conjugated silver nanoparticles in Balb/c mice, *J Clinical Gynaecology and Breast*, 3(4); **DOI:** 10.31579/2834-8427/30

Copyright: © 2024, Saiqa Andleeb. This is an open access article distributed under the Creative Commons Attribution License, which permits unrestricted use, distribution, and reproduction in any medium, provided the original work is properly cited.

Abstract

Background: Wound therapy is complicated, uncomfortable for the patient, and costly for the health-care system. Silver nanoparticles (AgNP) have antibacterial characteristics that can prevent bacterial infection in wounds and speed up wound healing **Objective:** The aim of current research was to investigate the wound healing and anti-inflammatory potential of biogenic synthesized silver nanoparticles (ABAgNP) using *Ajuga bracteosa* (ABaqu) in Swiss albino mice.

Methods: In vivo wound healing and anti-inflammatory activities were carried out using Balb/c mice. For in vivo screening of 200 mg/kg and 400 mg/kg of both ABAgNPs and ABaqu were used. Liver and kidney functional markers, hematology, and histopathological studies were carried out after 14 days of administration.

Results: The obtained biogenic nanoparticles were characterized, dermal toxicity, wound excision repairing, and formalin-induced paw edema assays were performed in Swiss albino mice. Dermal toxicity showed that tested concentrations of ABaqu and ABAgNPs were safe. No adverse effects, changes, and alteration in the skin of treatment groups as well as the control vehicle group (petroleum jelly) were recorded. Results revealed that the enhanced wound contraction was observed in ABaqu, ABAgNP, and the Nitrofurantoin treated groups from 7th to 11th days. The anti-inflammatory activity in formalin-induced paw edema model illustrated the potential use of silver nanoparticles ABAgNPs and ABaqu as a reducing or inflammation inhibiting agents due to the release of acute inflammatory mediators.

Conclusion: Therefore, it was concluded that both silver nanoparticles (ABAgNP) and *Ajuga bracteosa* (ABaqu) extracts could be used as a wound healing and anti-inflammatory agents.

Keywords: *ajuga bracteosa*; anti-inflammatory agents; silver nanoparticles; swiss albino mice; wound healing

Introduction

Wounds are physical injuries and commonly defined as “loss or breaking of cellular and anatomic or functional continuity of living tissues” [1, 2]. There

are two conditions related to wound such as chronic or acute wound [3, 4]. Chronic wounds occur due to medical issues and results in socioeconomic

crisis, disability, morbidity, and mortality of the large population [5]. During an injury, a blood clot is formed due to the damage in capillary and followed by the early phase of the inflammation. The mechanism of tissue regeneration completed in four main programmed phases that are hemostasis, inflammation, proliferation, and the maturation or remodeling [6]. Immune response to injury/wound or infection causes inflammation, results in the removal of some factors, physiological function, and tissue structure restoration [7]. Two types of drugs are used for the treatment of inflammation non-steroidal drugs and steroidal drugs. On the other hand, these types of drugs cause various side effects, so, it is the need to find alternative medicines that can solve the problems efficiently, well-tolerated, homeostatic, and modulatory via the body [8].

Infections related to various wounds, elevate medical expenditures and put a strain on health-care systems due to prolonged hospital admissions, treatment failures, infection persistence, and delayed wound healing, which often leads to amputation and increased death [9]. New antibiotics and antibacterial techniques are urgently needed to tackle infections in wounds. Chemically manufactured medications have several side effects; as a result, medicinal plants are being studied for their curative potential due to their widespread availability and lack of toxicity for therapeutic usage while being effective at preventing infections in different wounds [10]. Many researchers reported the use of herbal or traditional medicines for solving health issues [5, 11]. Plants or synthesis of medicine from the plant is considered an important source of recent medicines worldwide [12]. In most developing countries (like Ethiopia), the treatment of dermatological problems as well as skin disorders like wounds, burns, and cuts depend upon the use of medicinal plants that play the main role in wound healing [13-15, 2]. Products isolated from plants have been used as an effective anti-inflammatory agent having low toxicity and effective pharmacological property [16]. *Ajuga bracteosa* is a medicinal herb that grows from Azad Kashmir to Nepal at an elevation of 2000 meters in the sub-Himalayan tract. Its leaves are used to treat several diseases like stomach acidity, burns, boils, wound healing, hypertension, jaundice, and sore throats. It has also been demonstrated to have anti-inflammatory, anticancer, antimicrobial and antimalarial properties [17].

The best new alternative and effective procedure for the new drugs development and drug delivery related to inflammation is nanotechnology. It is the technique that is used to synthesize the product at a nano-level about 1-100 nm [18]. Metal nanoparticles and their effectiveness in fighting infectious diseases is an attractive area of research with many applications [19]. There are various nanoparticles but because of the potent antimicrobial properties against bacteria, viruses, and fungus, silver nanoparticles have been utilized for over a century. Furthermore, silver's anti-inflammatory properties as well as its ability to speed wound healing have recently been demonstrated [20]. Phyto-nanotechnology, in which nanoparticles are manufactured utilizing extracts from plants has attracted a lot of attention as a simple, quick, scalable, and cost-effective alternative. Plant extracts have the benefit of biocompatibility since they are high in bioactive chemicals that are amenable to extraction using water as an inert solvent and may also be used as reducing and capping agents in the creation of nanoparticles [21]. The inherent property of antibacterial suppression in antibiotic resistant bacteria has been reported in silver nanoparticles produced from plants that are widespread in secondary metabolites [22, 23]. Keeping in mind the importance of phytochemical assisted biogenic synthesis technique and medicinal significance of *A. bracteosa*, here we report the anti-inflammatory and wound healing effect of the synthesized biogenic silver nanoparticles using *A. bracteosa* (ABAgNP).

2. Materials and Method

2.1 Ethical statement

All experiments were appropriately performed in accordance with the Institutional Review Board (IRB) bioethics approval. The experiments have been designed to avoid distress, unnecessary pain and suffering to the experimental animals. All procedures were conducted in accordance with international regulations referred as *Wet op de dierproeven* (Article 9) of Dutch Law. Ethical approval has been provided by Office of Research Innovation and Commercialization (ORIC), University of Azad Jammu and

Kashmir, Muzaffarabad, Pakistan vide No. 649/ORIC/2021; Dated: 16-12-2021.

2.2 Chemicals used

All chemicals and reagents were obtained from Sigma Aldrich (Germany), Merck (Germany), and Sigma Aldrich (Switzerland). silver nitrate (AgNO_3), dimethyl sulphoxide (DMSO), formalin, petroleum jelly, nitrofurantoin, diethyl ether, formaldehyde, Diclofenac sodium.

2.3 Extract preparation, silver nanoparticles synthesis, and characterization

The roots and aerial parts of *A. bracteosa* were cleaned with the running tap water to remove dust and air-dried at room temperature ($20 \text{ }^\circ\text{C} \pm 2$) under shade. The dried material was crushed in to fine powder and used for the aqueous extract preparation via maceration [24]. Silver nanoparticles using ABaqui were synthesized by simple ratio method [25]. Briefly, aqueous extract was prepared by adding 10 g of root or aerial part powder to 100 mL of distilled water (1:10 ratio) and heated in a water bath at $50 \text{ }^\circ\text{C}$ for 40 min. The solution was then allowed to cool at room temperature (RT, $25 \text{ }^\circ\text{C}$) followed by filtration through Whatman filter paper (No. 1). 5 mL of this prepared extract was slowly added into 45 mL of silver nitrate (AgNO_3 , 1 mM) in an Erlenmeyer flask. The resultant mixture was adjusted to pH 7 and incubated on a rotary shaker at 200 rpm, in dark, for 24 h at RT. During this period, visual observations were made to detect any change in color. The synthesized nanoparticle suspension was centrifuged at 4,500 rpm for 20 min to collect ABAgNPs as a pellet. To ensure removal of unreacted silver ions and any unbound phyto-constituent, this pellet was washed thrice with distilled water, air-dried, and stored at room temperature for further use. The preliminary characterization of green synthesized nanoparticles (ABAgNPs) was done through a UV-viz spectrophotometer (between 200 nm to 800 nm). The morphology (shape and size) of ABAgNPs and ABaqui were confirmed through a scanning electron microscope (SEM). Fourier transform infrared spectroscopy (FTIR, Thermo Fischer Scientific) recorded the absorption spectra of dried pellets of ABaqui and ABAgNPs in the range of 4,000–400 cm^{-1} to identify the presence of functional groups involved in bio-reduction.

2.4 Experimental animal

The male Swiss albino mice (23-30 g) were purchased from the animal facility center of the National Institute of Health (NIH), Islamabad, Pakistan. The animals were acclimatized for 2 weeks before the beginning of the current research. Animals were maintained in individual cages with free access to food and water under controlled conditions (5 % humidity, 12 h day/night cycles, and the room temperature at $25 \pm 2 \text{ }^\circ\text{C}$). The handling and special care of the Swiss albino mice were according to the established public health guidelines in Guide for Care and Use of Laboratory Animals [26]. The feed (commercial chow) and water consumption patterns were observed throughout the study period.

2.5 Acute Dermal Toxicity

Acute dermal toxicity study was performed with a limit test at 1000 mg/kg (1 ml) as a single dose for both ABaqui and ABAgNPs according to the adopted procedures described previously with slight modifications [27]. The mice were selected randomly after acclimatization to the laboratory conditions, and kept in their cages for at least 5 days before dosing. Three groups having three healthy Balb C mice weighing 23–30 g was acclimatized such as group I treated with vehicle (petroleum jelly); group II animals treated with ABaqui; and group III animals treated with ABAgNPs. For acute dermal toxicity, the fur was removed 24 h before the study from the dorsal area of the trunk of the tested animals and the highest concentration of the ABaqui and ABAgNPs (1000 mg/kg) ointment 10% (w/w) for a period of 24 h were applied. The treatment was repeated for 14 days. After application, cage side observation was performed daily for the next 14 days to notice the late development of dermal toxicity [28]. Tissues from all the experimental treatments were collected at the end of the experiment by using sterile scissors and forceps for histopathological studies. The tissue samples were fixed in 10% formaldehyde for 1 week for the histological examination [29]. Water and food were provided to all animals regularly ad libitum.

2.6 Excision wound model

The wound-healing effect of ABAGNPs and ABAqu were evaluated in Swiss albino mice using the protocol of Sasidharan et al. [30] with slight modifications. Mice were anesthetized using diethyl ether (45 mg/kg) given by the intraperitoneal route. Fur was removed from the dorsal area and a full-thickness wound of approximately 1.5 cm x 1.5 cm was made on the shaved area. Six groups (n=6) were made for the wound healing evaluation; group I had no wound and used as normal control, group II wound was treated with vehicle (petroleum jelly), group III was not treated and left open, group IV was treated with nitrofurantoin ointment in petroleum jelly, group V was treated with *A. bracteosa* extract (ABAqu; 400 mg/kg), group VI was treated with synthesized silver nanoparticles (ABAGNPs; 400 mg/kg) using *A. bracteosa*. The decrease in wound diameters during the healing process was measured with the help of scale in millimeters. The wounded mice were kept for 14 days for the treatment and further observations. Tissues from mice wounds were collected at the end of the experiment by using sterile scissors and forceps for histopathological studies. The tissue samples were fixed in 10% formaldehyde for 1 week for the histological examination [29].

2.7 Formalin-induced paw edema

In vivo anti-inflammatory effect of *A. bracteosa* aqueous extract ABAqu (400 mg/kg), green synthesized ABAGNPs using *A. bracteosa* (400 mg/kg) were screened in Swiss albino mice (Balb/c) 31. The experiment was designed for 11 days. Swiss albino mice were divided into 6 groups (n=6) such as group I (Normal control), group II (vehicle; dH₂O), group III (2% formalin; 0.1 ml), group IV (2% formalin + Diclofenac sodium), group V (2% formalin + ABAqu; 400 mg/kg), and group VI (2% formalin + ABAGNPs; 400 mg/kg), and treated daily accordingly. Paw edema was induced by injection of 2% formalin (0.1 ml) into right hind paw of the rats [32]. The volume of formalin-induced paw edema was measured with Vernier-calliper after each hour up to 11th day, and compared with control during the experiment. At the end of the experiment (after 11th day) animals were sacrificed, blood and tissue samples were collected. The serum enzymes such as Alanine transaminase (ALT), Alkaline phosphatase (ALP), and Aspartate transaminase (AST) were determined using reported protocols (King, 1965). The hematological parameters like eosinophils, red blood cells, white blood cells, platelets, hematocrit, lymphocytes, neutrophils, monocytes, and hemoglobin were measured according to the standard procedures [33]. Tissues from mice wounds were collected at the end of the experiment by using sterile scissors and forceps for histopathological studies. The tissue samples were fixed in 10% formaldehyde for 1 week for the histological examination [29].

2.8 Statistical analysis

Each experiment was conducted thrice time. Statistical analyses were performed using graphpad prism for windows (version 5.03) and also used to plot graphs with error bars of standard errors of the means (SEM). 'a' indicates significant difference between control and diseased groups; 'b' indicates significant difference between control and other treatment groups;

'c' indicates significant difference between diseased and other treatment groups; 'd' indicates significant difference between vehicle and other treatment groups. 'e' indicates significant difference between positive control and ABAqu and ABAGNPs treated groups. Values are mean±sem(n=6). Statistical icons: single letter (a/b/c/d=p≤0.05); double letter (aa/bb/cc/dd =p≤0.01); triple letter (aaa/bbb/ccd= p≤0.001).

3. Results

3.1 Synthesis and characterization of nanoparticles

The synthesis of ABAGNPs was confirmed through the UV-Viz spectrum at 400 nm. The tube-like particles as well as several aggregates of nanoparticles with a diameter ranging from 5 μm up to 50 μm was recorded via SEM. The IR spectrum had shown bands correspond to O-H and H stretching and confirmed the presence of alcohol and phenol's, Carbonyl stretching, N-H and C-N stretching indicating the presence of aromatic amino groups and proteins. The absorption bands at 1108 cm⁻¹ and 1021 cm⁻¹ might have contributed by the C—O group of the polysaccharides.

3.2 Acute dermal toxicity

Results revealed that the maximum concentration of the ABAqu and ABAGNPs ointment (10% w/w) was not toxic and after 24 h, the dermal site did not show any sign of inflammation or irritation (Figure 1). No sign of toxicity was observed when the mice were followed for 48 h. Moreover, there was no mortality were detected during the 14 days. The hair growth was appeared and easily visualized in the ABAqu and ABAGNPs treated groups (Figure 1). Through histology no inflammatory cells were found in all treated groups. Not any difference was observed when ABAqu and ABAGNPs treated groups compared to vehicle treated group Normal epithelization was recorded (Figure 1). Therefore, we can say that ABAqu and ABAGNPs may be safe at 1000 mg/kg (10% w/w) and the oral LD50 is greater than tested dose in the Swiss albino mice. The WBC level was noted as slightly high in ABAqu treated animals and ABAGNPs treated animals (3.75±0.23 103/UL and 3.57±0.47 103/UL respectively) compared to vehicle treated group (3.47±0.638 103/UL). Level of RBC was recorded as slightly low in ABAqu treated animals (4.59±0.19 106/UL) and remains normal in ABAGNPs treated animals (4.8±0.19 106/UL) when compared to vehicle group (4.83±0.5 106/UL). Slight difference was noted in hemoglobin and hematocrit level of ABAqu treated animals. The hemoglobin level of ABAqu treated animals was 12.66±1.15 g/dl and remains normal in ABAGNPs treated animals (13.3±0.57 g/dl) compared to vehicle control group (13.0±1.0 g/dl) and there was no significant difference noted. Hematocrit level in vehicle was noted as 38 ± 8.1 % and was slightly high in both ABAqu (40.0±3.5 %) and slightly low in ABAGNPs (37.0±4.7 %). Platelets and Neutrophil levels slightly increased in both ABAqu and ABAGNPs treated animals respectively compared to (DH₂O) control group. Eosinophil, lymphocytes, monocytes, and MCV in both treated groups ABAqu and ABAGNPs showed no significant difference when compared to vehicle (DH₂O).

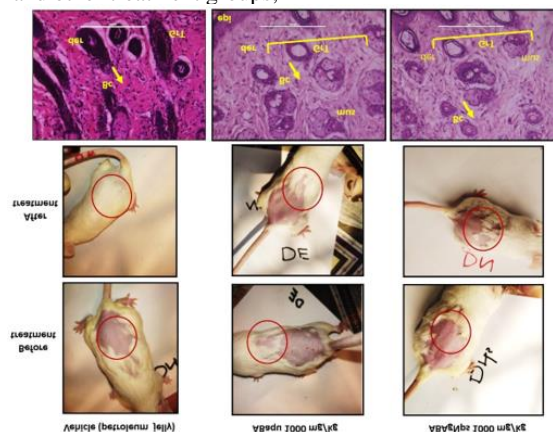


Figure 1. Effect of *Ajuga bracteosa* conjugated silver nanoparticles during acute dermal toxicity assay in Swiss albino mice.

3.3 Wound healing effect

The wound-healing activity of synthesized ABAGNPs was confirmed in Swiss albino mice using an excision wound model. The changes in the wound appearance were took place on 1st day, 3rd, 5th, 7th, 9th, and 11th day. On 3rd day Nitrofurantose, ABaqu, and ABAGNPs treated mice exhibited brown color, moist and soft scabs while vehicle (petroleum jelly) and open wound mice showed thick, hard and intact scabs. On 11th day, re-epithelialization was observed in Nitrofurantose, ABaqu, and ABAGNPs treated mice (Figure 2). The enhanced wound contraction in ABaqu, ABAGNPs, and the Nitrofurantose treated groups from 7th to 11th days were recorded. Both of the ointments (ABaqu and ABAGNPs) showed significant wound healing than open wound (control group). On 11th day, both Nitrofurantose and ABAGNPs showed 70% wound contraction rate compared to open wound group (10%), and vehicle (10%) and ABaqu (60%) treated groups. ABAGNPs treated wounds exhibited no evidence of pus formation and bleeding during treatment, whereas control wounds revealed the remarkable inflammation. At the end of the experiment, the ABAGNPs treated wound and Nitrofurantose treated groups showed approximately maximum of wound closure (3.0 ± 0.0 mm and 3.0 ± 0.1 mm) compared to vehicle (9.0 ± 0.1 mm) and ABaqu (4.0 ± 0.0 mm) treated groups. Histopathological examination revealed diffused inflammatory cells trapped, focal inflammatory cells infiltration, and area of hemorrhages in the open wound mice in which granulated tissue was not fully formed (Figure 3). In open wounded mice damage of epidermis, dermis and granular tissues were also recorded. On the other hand, in case of vehicle treated group epithelization, keratinization, and granulation was observed. ABaqu and ABAGNPs treated wound mice showed significant increase in epithelization and remarkable fibroblast proliferation (Figure 3). No inflammation was observed in Nitrofurantose, ABaqu and ABAGNPs treated groups.

Interestingly, ABAGNPs treated wound group showed complete epithelization with keratinization (Keratin covering), and fibrous connective tissue proliferation. New blood capillaries formation was also seen in Nitrofurantose, ABaqu and ABAGNPs treated groups (Figure 3).

3.4 Anti-inflammatory effect

Data revealed that formalin induced animals exhibited significant elevation of paw thickness immediately after 2 h ($P < 0.001$) of induction and regularly increased at each hour of the study period (Figure 4). Paw volume increased up to 5th day. On the other hand, the aqueous extract (ABaqu) and silver nanoparticles (ABAGNPs) significantly reduced the formalin induced paw edema at 400 mg/kg tested dose (Figure 4). The standard drug diclofenac sodium also showed the anti-inflammatory activity after 5th day of induction. Paw thickness was decreased in ABaqu treated formalin induced group from 0.8 ± 0.02 mm to 0.5 ± 0.1 mm as well as ABAGNPs formalin induced treated group (0.89 ± 0.02 mm to 0.6 ± 0.0 mm) compared to control and vehicle treated group (0.6 ± 0.1 mm) which had normal paw thickness throughout the studies. Formalin induced diseased group showed increase in paw thickness (0.6 ± 0.5 mm to 1.9 ± 0.1 mm) after few days (Figure 4). Results revealed that both ABaqu and ABAGNPs were able to reduce the inflammation at 400 mg/kg. Figure 4 shows the histological examination of formalin induced paw edema and anti-inflammatory effect of green synthesized silver nanoparticles (ABAGNPs) and ABaqu extract. Formalin induced paw showed the focal aggregations, infiltration of diffused and focal inflammatory cells, and overcrowding of edema. These inflammations were significantly reduced by the use of ABaqu and ABAGNPs. ABaqu treated mice showed a clear keratin covering, muscular cells, well developed dermis, and normal histopathological structure. ABaqu and ABAGNPs also reduced the focal aggregations in diseased treated mice.

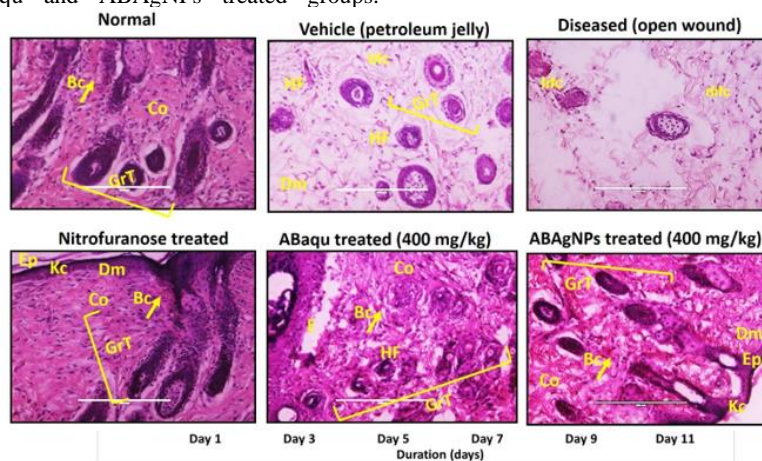


Figure 2. In vivo wound healing effect of *Ajuga bracteosa* conjugated silver nanoparticles.

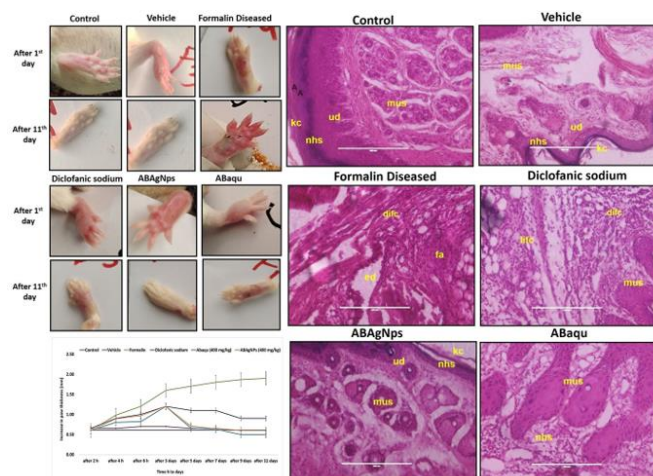


Figure 3. In vivo anti-inflammatory effect of *Ajuga bracteosa* conjugated silver nanoparticles.

Treatments → Parameter↓	Control	Vehicle DH ₂ O	Diseased (Formalin)	Diclofanic sodium (DF)	ABaqu (400 mg/kg)	ABAgNps (400 mg/kg)
WBC 10 ³ U/l	3.5±0.3	4.1±0.2	8.5±0.2	4.2±0.3	4.2±0.2	4.4±0.4
RBC 10 ⁶ /U/l	4.83±0.2	5.06±0.3	1.24±0.3	3.43±0.2	4.62±0.2	4.47±0.2
Hb g/dl	13.0±0.4	12.4±0.3	10.32±0.3	13.42±0.4	13.5±0.5	13.66±0.2
Platelets 10 ³ U/l	206.6±0.3	257.6±0.2	837±0.3	795.3±1.2	478.33±0.2	478.0±0.4
Neutrophils %	22.3±1.6	23.3±0.7	38.3±2.7	16.3±1.7	26.3±2.5	19.0±1.9
Eosinophils %	2.3±0.7	2.0±0.0	3.0±0.4	2.0±0.0	2.7±0.3	2.3±0.3
Lymphocytes %	71.3±3.2	70.7±5.0	86.0±2	78.3±2.3	78.0±4.3	76.7±5.6

Table 1. Anti-inflammatory impact of green synthesized silver nanoparticles (ABAgNPs) and ABaqu extract level of total WBC, RBC, Hemoglobin, and leucocytes against formalin induced paw edema in Swiss albino mice.

Values are mean ± SEM (n=6). p<0.05, p<0.01, p<0.001

The data presented in Table 1 revealed that WBC level was greater in formalin induced paw edema treated group compared to other group (8.5 ± 0.2 10³ μL) but it was noted that the WBC level was significantly reduced in diclofanic sodium treated group (4.2 ± 0.3103 μL), ABaqu and ABAgNps treated group (4.2± 0.2 103 μL and 4.4± 0.4 103 U/l, respectively). In control group the WBC level was noted as 3.5± 0.3 103 μL. It was noted that hemoglobin and red blood cells level was high in diseased mice (10.33±0.3106 μL and 1.24±0.3106 μL) while both were increased in ABaqu (13.57±0.5106 μL and 4.62±0.2 106 VL) and ABAgNps treated groups (13.66±0.2 106 μL and 4.47±0.2 106 uL) compared to others. The level of

platelets was increased in formalin induced paw edema mice (837.0 ± 0.3 103 μL). While the level of platelets was significantly reduced in ABaqu and ABAgNps treated group (478.33 ± 0.2 103 μL and 478.0 ± 0.4 103 U/l), respectively. There was increase in neutrophils level in formalin induced diseased group (38.3 ± 2.7%) when compared to control group (22.3± 1.6%) as well as diclofanic sodium treated group (16.3 ± 1.7%). Decreased level of neutrophils was observed in ABAgNps treated group (19.0 ± 1.9%). There was increase in lymphocytes and eosinophils level of formalin induced diseased group (86.0 ± 2% and 3.0± 0.4%). Lymphocyte's level was recorded as low in ABaqu (78.0± 4.3 %) and ABAgNps treated groups (76.7 ± 5.6 %).

Treatments → Parameter↓	Control	Vehicle DH ₂ O	Diseased (Formalin)	Diclofanic sodium (DF)	ABaqu (400mg/kg)	ABAgNps (400 mg/kg)
ALT U/L	46.0 ± 4.1	59.3 ± 2.5	121.7 ± 10.8	74.3 ± 2.9	95.0 ± 4.7	76.3 ± 3.4
AST U/L	41.0 ± 4.3	55.3 ± 4.9	112.7 ± 4.2	65.3 ± 3.8	81.0 ± 4.7	71.3 ± 4.5
ALP U/L	159.7 ± 8.6	172.3 ± 5.7	280.0 ± 11	142.3 ± 5.8	194.3 ± 8.4	175.7 ± 6.3

Table 2. Anti-inflammatory impact of green synthesized silver nanoparticles (ABAgNPs) and ABaqu extract on serum enzymes against formalin induced paw edema in Swiss albino mice.

Values are mean ± SEM (n=6). p<0.05, p<0.01, p<0.001

It was revealed that the ALT level elevated in formalin induced diseased mice group (121.7±10.8 U/L) compared to control groups. While the ALT level was reduced after treatment with standard drug (74.3±2.9 U/L). The significant reduction was recorded in ABaqu and ABAgNps treated animals (95.0±4.7U/L and 76.3±3.4 U/L) as well (Table 2). It was noted that AST level elevated in formalin induced diseased mice group (112.7 ± 4.2 U/L) compared to control groups. Results revealed that ABAgNps treated mice showed significant decrease in AST level (71.3 ± 4.5 U/L). ALP level found increased in formalin induced diseased mice group (280.0±11 U/L) compared to control groups. ABaqu and ABAgNps treated groups showed significant decreased in ALP level (194.3±8.4 U/L and 175.7±6.3 U/L) as shown in Table 2.

4. Discussion

Traditional medicinal plants are being investigated as a potential source of novel medications to combat the growing range of ailments and inflammatory diseases [34]. Various medicinal plants such as *Elaeis guineensis* [30] *Arnebia nobilis* [12] *Ampelopsis japonica* [35] and *Talinum fruticosum* [36] has been used for the assessment of wound healing and as an anti-inflammatory agent. The function of the healing process causes the restoration and replacement of damaged tissues [2] These new improvements and discoveries decreased serious complications and hospitalization regarding wound healing. [37] Silver nanoparticles have acquired prominent place in disease management because of their unique properties owing to small dimension and large surface area, mechanical and thermal stability, anti-inflammatory and antimicrobial activity [38]. In the current study, the descriptions of synthesis and characterization of ABAgNPs have been published by Nazer et al. [39]. The results of this study, following the guidelines of the OECD, showed that

ABaqu and ABAgNPs showed non-toxic effect on mice skin at a dosage of 1000 mg/kg body weight. Previous reported data was in agreement with recent study [40]. Hence, this study might explain the importance of investigating the safety use of ABaqu and ABAgNPs ointment on the skin. This finding demonstrates that the ABaqu and ABAgNPs ointment under study have no acute dermal toxicity. Moreover, no signs of toxicity as well as no mortality were noted during the 14 days of cage side observation. According to Hamed et al. [41] and Toker et al. [42] wound healing is a complex process that involves epithelization, inflammation, new tissue formation, and tissue remodeling. Previous literature showed that plant extracts are potential source of wound healing agents [43]. Various medicinal plants such as *Arnebia nobilis*, *Elaeis guineensis*, *Carapa guianensis* L., *Carica papaya* L., *Jasminum grandiflorum* Linn, *Rubus chamaemorus*, *Ampelopsis radix*, and *Ampelopsis japonica* showed significant wound healing effect in treated rats [44-46, 30, 12, 35]. In current research, the wound healing effect of *A. bracteosa* was screened in Swiss albino mice and our findings agreed with the previous literature. Researchers used green synthesized silver nanoparticles to cure the wound infections and inflammation [20, 12, 47] Current results are consistent with previous investigations. Green synthesized silver nanoparticles ABAgNPs using *A. bracteosa* had significant wound healing effect due to presence of pharmacologically active phyto-constituents such as flavonol glycosides, tannins, polyphenols, steroids, alkaloids, terpenoid, iridoid glycosides, reducing sugars, saponins, and flavonoids which play important role in wound healing process [48]. Younis et al. [49] reported showed significant antimicrobial together with wound healing abilities by biogenic AgNPs produced by *Phormidium* sp. Hematological studies revealed the low level of WBC, RBC and hemoglobin in open wound (diseased) groups compared to vehicle and other treated groups, which lead to cause inflammation at the site of wound and may be occurred due to oxidative stress that increase in

the production of free radicals. On the other hand, ABAqu, ABAGNPs and Nitrofurantose treated groups showed the significant increase in the hematological parameters. We can say that they involved in the reduction of free radicals due to presence of potent antioxidants (phenols and flavonoids). Some researchers have established antioxidant effects of medicinal plants which have importance to reduce the inflammation activities [50, 51, 36]. These antioxidants play an important role in wound healing. Our results are consistent with the findings of Sasidharan et al. [30], who reported that antioxidants of *Elaeis guineensis* has potent wound healing effect. High level of lymphocytes suppresses the inflammation response during wound healing.

Histochemical analysis revealed that early regeneration of epidermis, dermis, and keratin covering in ABAGNPs and Nitrofurantose treated groups compared to vehicle group. It is confirmed that ABAGNPs had a positive effect towards epithelization, granulation tissue formation, and cell proliferation. Sasidharan et al. [30] also showed the early tissue regeneration in *Elaeis guineensis* treated mice. Hematoxyline and eosin staining showed the well-synthesized collagen in wound treated groups (ABAqu, ABAGNPs and Nitrofurantose), which also support the potential effect of *A. bracteosa* on fibroblast proliferation and extracellular matrix synthesis during wound healing. Alkaloids and terpenoids *A. bracteosa* may be involved in the wound healing process as reported earlier by Garg et al. [52]

According to John and Shobana, [36] formalin induced paw edema in mice is one of the superlative practices to display the acute anti-inflammatory effect and is a time-dependent reaction. In current study, we observed that ABAqu and ABAGNPs significantly reduced the formalin induced paw edema at 3rd day of induction. This finding suggests the protective effect of green synthesized silver nanoparticles using *A. bracteosa* which has already been reported [53]. It may be due to the presence of phytochemical constituents of *Ajuga bracteosa* such as flavonoids, phenolic contents, and terpenoids which play an important role as anti-inflammatory agents. Our findings agreed with the [54-56]. Mazandarani et al. [57] reported that flavonoid and phenolic constituents of *N. officinale* play an important role as anti-inflammatory agent. Jang et al. [58] validated that AgNPs administration reduced inflammation by declining vascular endothelial

growth factor, PBK, and mucous glycoprotein expression in ovalbumin-induced allergy in murine model. Wong et al. [59] also reported that AgNPs possessed anti-inflammatory activity in postoperative peritoneal adhesion model. Yilma et al. [60] showed that silver-polyvinyl pyrrolidone nanoparticles exhibited anti-inflammatory activity by reducing TNF- α .

The high level of neutrophils, lymphocytes and eosinophils were recorded in the formalin induced paw edema treated mice. Previous literature reported that leucocytes play a major role in the manifestation and development of inflammation. High level of neutrophils produced free radicals and cytokines which are also responsible for inflammation development [36]. Generation of reactive oxygen species involved in the development of inflammation [61]. Eosinophils synthesize and release lipids derivatives which involved in the inflammation development in tissues while lymphocytes cause the tissue distortion at the site of inflammation [62]. On the other hand, ABAqu and ABAGNPs treated diseased mice significantly reduced the inflammation via decreasing the population of leukocytes. We can say that *A. bracteosa* possessed strong antioxidants (phenolics and flavonoids), play critical role in the inflammation activities. The occurrence of the saponin as plant secondary metabolites are mainly responsible for anti-inflammatory property [63, 64]. Some researchers have established antioxidant effects of medicinal

plants which have importance to reduce the inflammation activities [50, 51, 36] Hemoglobin and RBC play a major role in the oxygen transport. Formalin induced paw edema mice indicated the significant decrease in the RBC and Hb which leads to cause anemia. Our findings bear a resemblance to the previous study of Agnel et al. [62]. Similarly, the level of WBC was also increased which are responsible for the production of granulocytes stimulating factors, and involved in the development of inflammation [36]. The increased level of serum enzymes such as AST, ALT and ALP play an important role in the development of both chronic and acute inflammation. Our results are consistent with the findings of Sudharameshwari and Maheshwari [65]. The role of ABAqu and ABAGNPs against formalin induced paw edema is shown in figure 5.

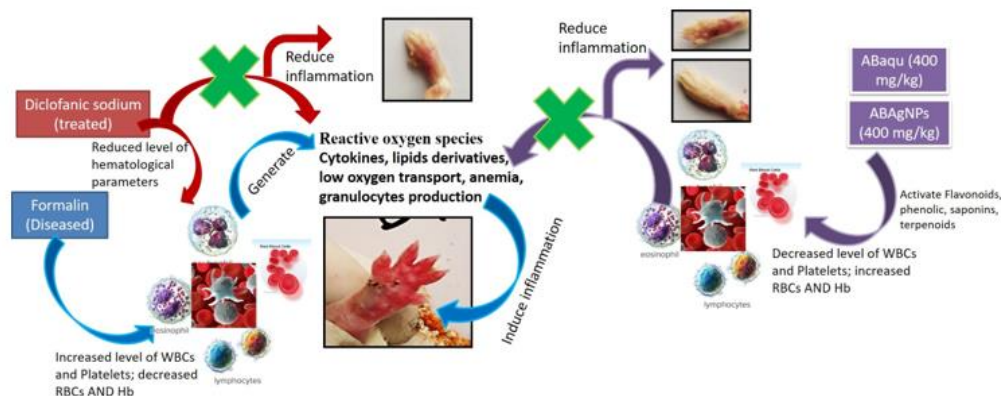


Figure 5. Role of *Ajuga bracteosa* conjugated silver nanoparticles and ABAqu in formalin induced paw edema Swiss albino mice.

Conclusion

In conclusion, the present experimental findings of hematological, histopathological, suggests that silver nanoparticles *Ajuga bracteosa* is a promising anti-inflammatory agent in the treatment of inflammation. The phytochemical screening of the plant source contains flavonoids that confirms anti-inflammatory potential of *Ajuga bracteosa*. The excision wound model showed comparable wound healing with that of standard. ABAGNPs showed faster and more effective wound healing activities than standard drug and petroleum jelly in the skin of experimentally scalded mice. Histopathological evaluation results showed better re-epithelialization, vascularization, granulation tissue formation.

Ethics Approval and Consent to Participate

The manuscript has been read and approved by all the authors and that the criteria for authorship have been met.

Human And Animal Rights

All experiments have been designed to avoid distress, unnecessary pain and suffering to the experimental animals. All procedures were conducted in accordance with international regulations referred as Wet op de dierproeven (Article 9) of Dutch Law.

Consent For Publication

The approval for publication of this article has been taken from all the authors.

Conflict Of Interest

There is no financial, reviewing or other conflict of interests.

Funding

No

Acknowledgements

Authors are grateful to the Department of Physics, University of Azad Jammu and Kashmir, Muzaffarabad and National Institute for Lasers and Optronics (NILOP), Pakistan Atomic Energy Commission, Islamabad, Pakistan, for providing research facilities.

References

- Pillai SI, Palsamy P, Subramanian S, Kandaswamy M. Wound healing properties of Indian propolis studied on excision wound induced rats. *Pharm Biol.* 2010; 3: 1–9.
- Nagori BP, Solanki R. Role of Medicinal Plants in Wound Healing. *Res. J. Med. Plants.*, 2011; 5: 392-405.
- Bowle PG. Wound pathophysiology, infection and therapeutic options. *Ann.Med.* 2002; 34: 419–27.
- Franz MG, Robson MC, Steed DL, Barbul A, Brem H, Cooper DM, et al. Guidelines to aid healing of acute wounds by decreasing impediments of healing. *Wound Repair and Regen.* 2008; 16: 723–48.
- Kokane DD, More RY, Kale MB, Nehete MN, Mehendale PC, Gadgoli CH. Evaluation of wound healing activity of root of *Mimosa pudica*. *J Ethnopharmacol.* 2009; 124: 311–5.
- Robson MC, Steed DL, Franz MG. Wound healing: biologic features and approaches to maximize healing trajectories. *Curr Probl Surg.* 2001; 38(2): 72–140.
- Ricciotti E, FitzGerald GA. Prostaglandins and inflammation. *Arteriosclerosis Thrombosis and Vascular Biol.* 2011; 31: 986–1000.
- Recio MC, Andujar I, Rios JL. Anti-inflammatory agents from plants: progress and potential. *Curr Med Chem.* 2012; 19: 2088–2103.
- WHO? Antimicrobial resistance. Geneva: World Health Organization. Getahun, H.; Smith, I.; Trivedi, K.; Paulin, S.; Balkhy, H.H. Tackling antimicrobial resistance in the COVID-19 pandemic. *Bulletin of the World Health Organization.* 2020; 1: 98(7), 442.
- Chinnasamy G, Chandrasekharan S, Bhatnagar S. Biosynthesis of silver nanoparticles from *Melia azedarach*: Enhancement of antibacterial, wound healing, antidiabetic and antioxidant activities. *Int J nanomed.* 2019; 14: 9823.
- Robinson MM Zhang X. The world medicines situation; Traditional medicines: Global situation, issues and challenges. Geneva, Switzerland: World Health Organization., 2011; 1–12.
- Garg P, Sardana S. Pharmacological and therapeutic effects of *Ocimum sanctum*. *Eur J Pharm and Med Res.* 2016; 3(8): 637–640.
- Patel JD, Shrivastava AK, Kumar V. Evaluation of some medicinal plants used in traditional wound healing preparations for antibacterial property against some pathogenic bacteria. *J Clin Immunol Immunopathol Res.* 2009, 1(1), 007–12.
- Annan, K.; Houghton, P. J. Antibacterial, antioxidant and fibroblast growth stimulation of aqueous extracts of *Ficus asperifolia* Miq. and *Gossypium arboreum* L., wound healing plants of Ghana. *J Ethnopharmacol.* 2008; 119: 141–4.
- Raina R, Prawez S, Verma PK, Pankaj, NK. Medicinal plants and their role in wound healing. *Vet Scan.* 2008; 3(1): 1–7.
- Anilkumar, M. Ethnomedicinal plants as antiinflammatory and analgesic agents. *Ethnomedicine: Complement Therap.* 2010; 267-293.
- Kaithwas G, Gautam R, Jachak SM, Saklani A. Antiarthritic effects of *Ajuga bracteosa* Wall ex Benth. in acute and chronic models of arthritis in albino rats. *Asian Pac J trop biomed.* 2012; 2(3):185-8.
- Galdiero S, Falanga A, Vitiello M, Cantisani M, Marra V, Galdiero M. Silver Nanoparticles as Potential Antiviral Agents. *Molecules.* 2011; 16: 8894-8918.
- Lee NY, Ko WC, Hsueh PR. Nanoparticles in the treatment of infections caused by multidrug-resistant organisms. *Front pharmacol.* 2019; 4: 10:1153.
- Kwan KHL, Liu X, Yeung KWK, Ho C, To MKT, Wong KK. Modulation of collagen alignment by silver nanoparticles results in better mechanical properties in wound healing. *Nanomed.* 2011; 7: 497.
- Noruzi, M. Biosynthesis of gold nanoparticles using plant extracts. *Bioprocess biosys eng.* 2015; 38(1):1-4.
- Jain S, Mehata MS. Medicinal plant leaf extract and pure flavonoid mediated green synthesis of silver nanoparticles and their enhanced antibacterial property. *Sci Rep.* 2017; 7(1): 1-3.
- Loo YY, Rukayadi Y, Nor-Khaizura MA, Kuan CH, Chieng BW, Nishibuchi M. In vitro antimicrobial activity of green synthesized silver nanoparticles against selected gram-negative foodborne pathogens. *Front microbiol.* 2018; 16(9):1555.
- Hafeez K, Andleeb S, Ghousa T, Mustafa RG, Naseer A, Shafique, I, et al. Phytochemical screening, alpha-glucosidase inhibition, antibacterial and antioxidant potential of *Ajuga bracteosa* Extracts. *Curr Pharm Biotechnol.* 2017; 18(4): 336-342.
- Kalishwaralal K, BarathManiKanth S, Pandian SR. Silver nanoparticles impede the biofilm formation by *Pseudomonas aeruginosa* and *Staphylococcus epidermidis*. *Colloids Surf B Biointerfaces.* 2010; 79: 340-344.
- Guide for the Care and Use of Laboratory Animals, 8th edition National Research Council (US) Committee for the Update of the Guide for the Care and Use of Laboratory Animals. Washington (DC): National Academies Press (US); 2011.
- Sari LM, Suyatna FD, Subita GP, Auerkari EI. Acute dermal toxicity study of *Areca catechu* Linn. Extract in sprague-dawley rats. *Asian J Pharm Clin Res.* 2016; 9 (3): 1-3.
- British Pharmacopoeia, Department of health and social security Scottish home and health department, office of the British Pharmacopoeia commission. UK, 1988.
- Sadeghi H, Zarezade V, Sadeghi H, Toori MA, Barmak M.J, Azizi A, et al. Anti-inflammatory Activity of *Stachys Pilifera* Benth. *Iranian Red Crescent Med J.* 2014; 16(9): 19259.
- Sasidharan, S.; Logeswaran, S.; Latha, L.Y. Wound Healing Activity of *Elaeis guineensis* Leaf Extract Ointment. In. *J Mol Sci.* 2012; 13: 336-347.
- Amresh G, Reddy GD, Rao C, Singh PN. Evaluation of anti-inflammatory activity of *Cissampelos pareira* root in rats. *J Ethnopharmacol.* 2007; 110: 526–31.
- Fotio AL, Dimo T, Nguenefack TB. Acute and chronic antiinflammatory properties of the stem bark aqueous and methanol extracts of *Sclerocarya birrea* (Anacardiaceae). *Inflammopharmacol.* 2009; 17: 229–37
- Armour D, Blood FR, Belden DA. The manual for laboratory work in mammalian physiology, 3rd ed., The University of Chicago Press, Chicago. 1964; 4-6.
- Anand U, Jacobo-Herrera N, Altemimi A, Lakhssassi N. A Comprehensive Review on Medicinal Plants as Antimicrobial Therapeutics: Potential Avenues of Biocompatible Drug Discovery. *Metabolites.* 2019; 9(11): 258.
- Lee K, Lee B, Lee MH, Kim B, Chinannain KS, Ham I, et al. Effect of *Ampelopsis radix* on wound healing in scalded rats. *BMC Complement Altern Med.* 2015; 15(1): 213.
- John ANA, Shobana G. Anti-inflammatory activity of *Talinum fruticosum* L. on formalin induced paw edema in albino rats. *J Appl Pharm Sci.* 2012; 02 (01): 123-127.
- James O, Victoria IA. Excision and incision wound healing potential of *Saba florida* (benth) leaf extract in *Rattus norvegicus*. *Int J Pharmand Biomed Res.* 2010; 1(4): 101–7.
- Rai M, Deshmukh S, Ingle A, Gade A. Silver nanoparticles: the powerful nanoweapon against multidrug-resistant bacteria. *J Appl Microbiol.* 2012; 112: 841–852.

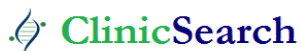39. Nazer S, Andleeb S, Ali S, Gulzar N, Raza A, Khan H, et al. Cytotoxicity, Anti-Diabetic, and Hepato-Protective Potential of *Ajuga bracteosa*-conjugated Silver Nanoparticles in Balb/c Mice. *Curr Pharma Biotechnol.* 2022; 23(3): 318-336.
40. Mulisa E, Asres K, Engidawork E. Evaluation of wound healing and anti-inflammatory activity of the rhizomes of *Rumex abyssinicus* J. (*Polygonaceae*) in mice. *BMC Complement Altern Med.* 2012; 151-341.
41. Hamed S, Ullmann Y, Masoud M, Hellou E, Khamaysi Z, Teot L. Topical erythropoietin promotes wound repair in diabetic rats. *J Invest Dermatol.*, 2010; 130: 287-294. Toker S, Gulcan E, Caycı MK, Olgun EG, Erbilin E, Ozay Y. Topical atorvastatin in the treatment of diabetic wounds. *Am J Med Sci.* 2009; 338: 201-204.
42. Chong, K.H.; Zuraini, Z.; Sasidharan, S.; Devi, P.V.K.; Latha, L. Y.; Ramanathan, S. Antimicrobial of *Elaeis guineensis* leaf. *Pharmacology online.* 2008; 3: 379-386.
43. Thiem B, Goslinska O. Antimicrobial activity of *Rubus chamaemorus* leaves. *Fitoterapia.* 2004; 75: 93-95.
44. Nayak BS, Kanhai J, Milne DM, Swanston WH, Mayers S, Eversley M, et al. Investigation of the wound healing activity of *Carapa guianensis* L. (*Meliaceae*) bark extract in rats using excision, incision, and dead space wound models. *J Med Food.* 2010; 13: 1141-1146.
45. Nayak BS, Mohan K. Influence of ethanolic extract of *Jasminum grandiflorum* Linn flower on wound healing activity in rats. *Indian J Physiol Pharmacol.* 2007; 51: 189-194.
46. Jan H, Zaman G, Usman H, Ansir R, Drouet S, Gigliolo-Guivarc'h N, et al. Biogenically proficient synthesis and characterization of silver nanoparticles (Ag-NPs) employing aqueous extract of *Aquilegia pubiflora* along with their in vitro antimicrobial, anti-cancer and other biological applications. *J Mater Res technology.* 2021; 1(15): 950-68.
47. Afreen A, Ahmed R, Mehboob S, Tariq M, Alghamdi HA, Zahid AA, et al. Phytochemical-assisted biosynthesis of silver nanoparticles from *Ajuga bracteosa* for biomedical applications. *Mater Res Express.* 2020; 24: 7(7) 075404.
48. Younis NS, El Semary NA, Mohamed ME. Silver nanoparticles green synthesis via *Cyanobacterium phormidium* sp.: characterization, wound healing, antioxidant, antibacterial, and anti-inflammatory activities. *Eur Rev Med Pharmacol Sci.* 2021; 1:25(7): 3083-96.
49. Yazdanparast R, Bahramikia S, Ardestani A. *Nasturtium officinale* reduces oxidative stress and enhances antioxidant capacity in hypercholesterolaemic rats. *Chem Biol Interact.* 2008; 172: 176-84.
50. Bahramikia S, Yazdanparast R. Antioxidant efficacy of *Nasturtium officinale* extracts using various in vitro assay systems. *JAMS.* 2010; 3: 283-90.
51. Garg S, Chandra A, Mazumder A, Mazumder R. Green synthesis of silver nanoparticles using *Arnebia nobilis* root extract and wound healing potential of its hydrogel. *Asian J Pharm sci.* 2014; 8: 95
52. Ahmed RH, Mustafa DE. Green synthesis of silver nanoparticles mediated by traditionally used medicinal plants in Sudan. *Int Nano Lett.* 2020; 10: 1-14.
53. Muthaiah NS, Viewanathan S, Thirugan-Sambanathan P, Reddy MK, Vijatalakshmi V. *Indian J Pharmacol Sci.* 1993; 55(5): 180-183.
54. Sone Y, Moon JK, Mai TT, Thu NN, Asano E, Yamaguchi K, et al. Antioxidant/anti-inflammatory activities and total phenolic content of extracts obtained from plants grown in Vietnam. *J Sci Food Agric.* 2011; 91: 2259-64.
55. Peluso I, Raguzzini A, Serafini M. Effect of flavonoids on circulating levels of TNF-alpha and IL-6 in humans: A systematic review and meta-analysis. *Mol Nutr Food Res.* 2013; 57: 784-801.
56. Mazandarani M, Momeji A, Zarghami MP. Evaluation of phytochemical and antioxidant activities from different parts of *Nasturtium officinale* R. Br. in Mazandaran. *Iran J Plant Physiol.* 2012; 3: 659-64.
57. Jang S, Park JW, Cha HR, Jung SY, Lee JE, Jung SS, et al. silver nanoparticles modify VEGF signaling pathway and mucus hypersecretion in allergic airway inflammation. *Int J Nanomed.* 2012; 7: 1329-43.
58. Wong KK, Cheung, SO, Huang Niu J, Tao C, Ho CH, Che M, et al. Further evidence of the anti-inflammatory effects of silver nanoparticles. *Chem Med Chem.* 2009; 4: 1129-1135.
59. Yilma AN, Singh SR, Dixit S, Dennis VA. Anti-inflammatory effects of silver-polyvinyl pyrrolidone (Ag-PVP) nanoparticles in mouse macrophages infected with live *Chlamydia trachomatis*. *Int J Nanomed.* 2013; 8: 2421-32.
60. Vircheva S, Nenkova G, Georgieva A, Alexandrova A, Tzvetanova E, Mateeva P, et al. Effects of desipramine on the antioxidant status in rat tissues at carrageenan induced paw inflammation. *Cell Biochem Funct.* 2011; 30: 18-23.
61. Agnel N, John A, Shobana G. Antiinflammatory activity of *Talinum fruticosum* l. On formalin induced paw edema in albino rats. *J Appl Pharm Sci.* 2012; 02(01): 123-127.
62. Tron GC, Piralı T, Richard A, Billington PLC, Giovanni-Sorba AAG. *Med Res Rev.* 2012; 29: 1292-1327.
63. Steenackers H, Ermolat'ev D, Trang TTT, Savalia B, Sharma UK, De Weerd A. et al. *Org Biomol Chem.* 2014; 12: 3671- 3678
64. Sudharameshwari K, Maheshwari V. *Cissus quadrangularis* extract mediated green synthesis of silver nanoparticles: pharmacological applications. *Indian J Med Res Pharm.* 2017; 2349-5340.

Ready to submit your research? Choose ClinicSearch and benefit from:

- fast, convenient online submission
- rigorous peer review by experienced research in your field
- rapid publication on acceptance
- authors retain copyrights
- unique DOI for all articles
- immediate, unrestricted online access

At ClinicSearch, research is always in progress.

Learn more <https://clinicsearchonline.org/journals/clinical-gynaecology-and-breast>



© The Author(s) 2024. **Open Access** This article is licensed under a Creative Commons Attribution 4.0 International License, which permits use, sharing, adaptation, distribution and reproduction in any medium or format, as long as you give appropriate credit to the original author(s) and the source, provide a link to the Creative Commons licence, and indicate if changes were made. The images or other third-party material in this article are included in the article's Creative Commons licence, unless indicated otherwise in a credit line to the material. If material is not included in the article's Creative Commons licence and your intended use is not permitted by statutory regulation or exceeds the permitted use, you will need to obtain permission directly from the copyright holder. To view a copy of this licence, visit <http://creativecommons.org/licenses/by/4.0/>. The Creative Commons Public Domain Dedication waiver (<http://creativecommons.org/publicdomain/zero/1.0/>) applies to the data made available in this article, unless otherwise stated in a credit line to the data.