

Hemoperitoneum Due to Trauma in the Superior Pancreatic Artery

Yarenis Perez Arias ¹, Pedro Rolando López Rodríguez ^{2*}

¹ First Degree Specialist in General Surgery, Instructor Professor.

² First and second degree specialist in general surgery, Assistant Professor, Consulting Professor and Assistant Researcher.

***Correspondence Author:** Pedro Rolando López Rodríguez, First and second degree specialist in general surgery, Assistant Professor, Consulting Professor and Assistant Researcher.

Received Date: January 06, 2023 | **Accepted Date:** January 17, 2023 | **Published Date:** January 27, 2023

Citation: Yarenis P. Arias., López Rodríguez PR, (2023), Hemoperitoneum Due to Trauma in the Superior Pancreatic Artery *Clinical Trials and Case Studies*, 2(1); **DOI:**10.31579/2835-835X/015

Copyright: © 2023, Pedro Rolando López Rodríguez. This is an open-access article distributed under the terms of the Creative Commons Attribution License, which permits unrestricted use, distribution, and reproduction in any medium, provided the original author and source are credited.

Abstract

Introduction: Abdominal trauma, specifically hemoperitoneum due to retroperitoneal injury, represents a challenge for the surgeon who works in the emergency department. Hemoperitoneum due to rupture of a branch of the dorsal superior pancreatic artery is not frequent; the pancreas is a retroperitoneal organ that, due to its location, is difficult to be affected by trauma.

Objective: to contribute to medical knowledge by presenting a case of hemoperitoneum due to a lesion in a branch of the superior pancreatic artery.

Material and method: Description of a clinical case and review of the literature.

Presentation of the case: a 51-year-old male patient, with a history of chronic alcoholism, who was admitted to the hospital in the surgery department for having had a blunt abdominal trauma of two days of evolution, had intense diffuse abdominal pain, did not expel feces or gas, tachycardic, with an abdominal ultrasound that reported free fluid in the cavity. He was taken to the operating room, finding hemoperitoneum due to a retroperitoneal bleeding lesion, specifically from a bleeding vessel from the superior dorsal pancreatic artery. After surgery, the patient evolved favorably and was discharged.

Conclusions: hemoperitoneum due to pancreatic artery injury is not frequent, so sometimes there is a delay in the diagnosis, which threatens a good patient evolution, which justifies the morbidity and mortality in these cases.

Keywords: abdominal trauma; hemoperitoneum; pancreas trauma

Introduction

In the context of abdominal trauma, injuries to the abdominal viscera are associated and rarely (in less than 5% of cases) the pancreas is individually affected, occurring in only 3% of abdominal traumas that require surgery. Abdominal trauma in general has a high morbidity and mortality, abdominal injuries represent between 20% and 35% of the causes of death in polytrauma patients. Hemoperitoneum due to rupture of a branch of the dorsal superior pancreatic artery is not frequent. The pancreas is a retroperitoneal organ that, due to its location, is difficult to be affected by trauma, and when this occurs, there are usually injuries to neighboring organs and vascular structures, which increases its risk. Abdominal vascular injuries are among the most lethal injuries suffered by multiple trauma patients, they are among the most difficult and challenging for surgeons, especially when they are retroperitoneal. Among the symptoms, the patient will present diffuse abdominal pain, peritoneal reaction that is related to hemoperitoneum, mucosal skin pallor, tachycardia, hypotension caused by hypovolemia, and other symptoms that are related to neighboring affected structures. Mortality from these injuries is very high, so rapid diagnosis of this entity is of vital importance.

Presentation of the case

A 51-year-old male patient with a history of chronic alcoholism and bronchial asthma admitted to the Surgery service, with a history of blunt abdominal trauma of two days' evolution and another of only one day's evolution. He arrives referring to intense diffuse abdominal pain of sudden onset that increased accompanied by abdominal distension and the non-expulsion of feces or gas. On physical examination, he found dry and hypocolor mucous membranes, at the beginning he found high blood pressure figures, which gradually decreased to 90 / 70mmHg, with heart rate; 120 per minute, respiratory rate 18 per minute, the abdomen did not follow the respiratory movements, distended, painful to superficial palpation throughout the abdomen with peritoneal reaction as well as dullness to percussion on both flanks, pain on rectal examination in the I had an empty rectal ampoule. Within the laboratory tests, a hematocrit was performed: 0.43, a 15x10 leukogram, as well as a simple standing abdominal X-ray where distension of the colic framework was observed, with a predominance of the transverse and descending colon, with an air-fluid level in said place. In the FAST ultrasound performed, distended intestinal loops and free fluid in the fornix of Douglas and left parietocolic

cavity were reported as positive. After the hemodynamic stabilization of the patient, surgical intervention was decided, finding 1000ml of blood in the entire peritoneal cavity, it was explored, not finding any viscus lesion, it was decided to explore the retroperitoneum where 500ml of blood was found with abundant clots and an actively bleeding vessel being a branch

of the dorsal superior pancreatic artery, this branch is ligated, thus stopping the bleeding, thus concluding the surgery. Despite the blood loss, the patient remained stable during surgery and in the recovery room, for which he was transferred to the Surgery room where he evolved favorably and was discharged on the 5th day.

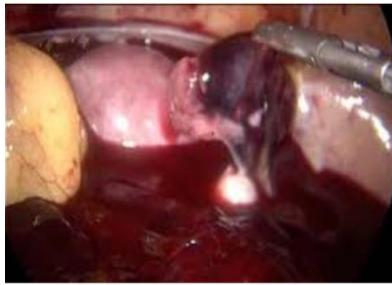

Figure 1: Retroperitoneal hemoperitoneum

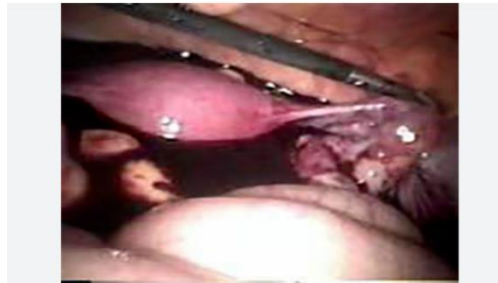

Figure 2: Hemoperitoneum Found

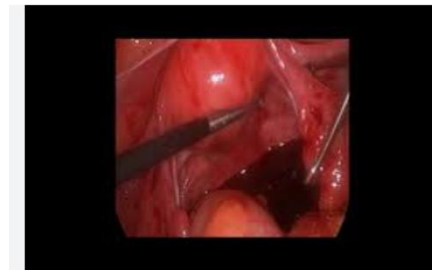


Figure 3: Diagnosed hemoperitoneum.

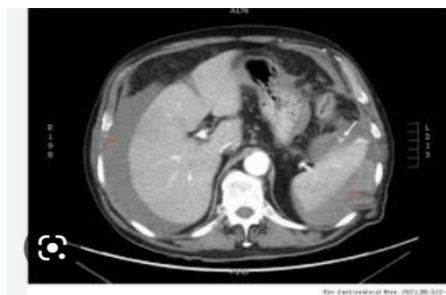

Figure 4: Vision of the Multislice CT carried out. Vision of the Multislice CT carried out.

Discussion

Worldwide, it has been reported that up to 90% of the causes of hemoperitoneum are due to blunt abdominal trauma. Patients with retroperitoneal wounds deserve special importance since the organs found in that place are more difficult to evaluate, and sometimes present late symptoms, so timely diagnosis and treatment are delayed, increasing mortality.⁴

Both blunt and penetrating abdominal trauma can injure retroperitoneal organs. Retroperitoneal hematoma can occur in blunt trauma, a complicated entity since the surgeon has to decide whether or not to explore it, exposing himself to massive hemorrhage that is difficult to

control or running the risk of overlooking a visceral or vascular lesion. The penetrating agents, whether by a knife or by fire, can penetrate through the anterior or posterior abdominal wall, entering directly into the retroperitoneum, making it a difficult case to diagnose.⁵

Various pathophysiological mechanisms can occur in blunt abdominal trauma, an increase in intra-abdominal pressure caused by external forces that can break viscera, especially hollow ones. The force exerted against the anterior abdominal wall can compress the abdominal viscera and cause splenic rupture. The shearing forces created by the sudden deceleration can cause injury to the intima and media of the arteries.⁴

When trauma occurs, the involvement of the pancreatic vessels (the pancreas is a highly vascularized organ) can cause local bleeding, usually causing a retroperitoneal hematoma. The existence of associated hemoperitoneum may be due to damage to neighboring intraperitoneal structures, a tear in the peritoneum, or the passage of blood from the extraperitoneal space.^{1,6}

Craig found hemoperitoneum in 5 of 13 cases of pancreatic trauma secondary to bleeding from lesions in other intraperitoneal organs. If there is a passage from the extraperitoneal space, the blood that escapes from the pancreas is located in the space adjacent to the bleeding site and is dissected through the omentum, peritoneum, or retroperitoneum cavity, even penetrating the mediastinum.⁷

Associated lesions: in a study of 4,559 patients with pancreatic lesions, who presented 9,11 intra-abdominal associated lesions (1.9 lesions per patient), the most frequent liver with 1,899 (20%) followed by gastric 1,564 (17.2%) and 1,305 major vascular (14.3%).⁸

The symptoms vary depending on the severity of the bleeding, the time of evolution and the type of trauma. The most common symptom is diffuse abdominal pain, abdominal contracture, decreased peristalsis associated with hemoperitoneum as in the case at hand, there may also be abdominal distension, dizziness, nausea and mucosal skin pallor, in severe cases hemodynamic instability may occur and even hypovolemic shock requiring urgent surgery.⁹

Among the complementary laboratory tests that help with the diagnosis is the hematocrit, which should be decreased, and amylase, which rises in up to 82% of cases.¹

Within imaging, computerized axial tomography is the one of choice to assess retroperitoneal structures,¹ along with abdominal ultrasound, which has a high sensitivity to determine the presence of free fluid in the abdominal cavity. Both puncture and peritoneal lavage can give rise to false positives and negatives. In vascular lesions, angiography would be the one of choice.¹⁰

The treatment that was carried out in this case was exploratory laparotomy with subsequent action, ligating a branch of the dorsal superior pancreatic artery that was actively bleeding in the retroperitoneum. There are multiple treatments for vascular lesions such as endovascular treatment by embolization or thrombin injection, as well as stents, among others.

Conclusions

In abdominal trauma, whether penetrating or blunt, the pancreas is not frequently affected, especially its vessels, so these injuries can go unnoticed at the first moment of the patient's evaluation. The delay in its

detection leads to a substantial increase in morbidity and mortality rates, so it is considered very important to take this type of retroperitoneal injury into account, especially in large-scale traumas in patients with hemodynamic instability, since when they go unnoticed threatens the life of the patient.

Conflict of Interests

The authors declare that does not exist an interest conflict.

Reference

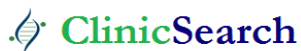1. Córdoba López, J. Monterrubio V, Bueno Álvarez-Arena, G. Corcho Sanchez. Traumatismo Pancreático aislado y hemoperitoneo una asociación infrecuente. *Emergencias* Vol.15 pág. 272.374.
2. F Henao; MD, SCC; HBohorquez; MD; J. Arias.MD, Diagnóstico y tratamiento del trauma retroperitoneal. *Rev.col.cirugia*. Vol. 8 N° 2.
3. Patrizio Petrone, Moral Álvarez, González Pérez, Ceballos Espárragos. (2017) Orientación terapéutica del trauma pancreático: revisión de la literatura. *Cirugía española*. Vol. 95 N°3 pag.123-130.
4. Toa Poca Ajitemberg. (2022) Stephanie Giselle, M. Quisang.Trauma abdominal cerrado. Manejo inicial en urgencias. *Raimundo*. Vol6. N°2.
5. Martínez Yaiza, Cas Estefanía. Castan Néstor, Main Domingo. Delfeau Daniel. Traumatismo pancreático duodenal: revisión de la literatura. *Rev. sanitaria de investigación*.
6. OrdoñezCA, Parra M, Millan, Caicedo Y, Padilla N, García A, et al. (2021) Dagame control in penetrating duodenal trauma: less is better. *Colombia Medica*. 6,52(2): e4104509.
7. Warren MH, Bhattacharya B, Maung AA, Davis KA. (2020) Contemporary management of spontaneous retroperitoneal and rectus sheath hematomas. *Am J Surg*. 219(4):707-710.
8. Kuza CM, Hirji SA, Englum BR, et al. (2020) Pancreatic injuries in abdominal trauma: US Outcomes, and predictors of Mortality. *Scand J Surg* 109:193.
9. Méndez, P.R.C; Martínez, D. R; Fonseca; R.S. S; Arzuaga, R. LG; & Suarez, M.D.J.P(2022). Evaluación de índices pronósticos del trauma abdominal cerrado. *Revista cubana de cirugía*,58(4),1-13.
10. Sánchez- Hernández, A.E; Marin-Gonzalez, I; Luna Álvarez; Steven-Aparicio, B, Cabrera-Vargas, L.F; Loia, S; & Marmolejo, S. (2021).

Ready to submit your research? Choose ClinicSearch and benefit from:

- fast, convenient online submission
- rigorous peer review by experienced research in your field
- rapid publication on acceptance
- authors retain copyrights
- unique DOI for all articles
- immediate, unrestricted online access

At ClinicSearch, research is always in progress.

Learn more <https://clinicsearchonline.org/journals/clinical-trials-and-case-studies>



© The Author(s) 2023. **Open Access** This article is licensed under a Creative Commons Attribution 4.0 International License, which permits use, sharing, adaptation, distribution and reproduction in any medium or format, as long as you give appropriate credit to the original author(s) and the source, provide a link to the Creative Commons licence, and indicate if changes were made. The images or other third party material in this article are included in the article's Creative Commons licence, unless indicated otherwise in a credit line to the material. If material is not included in the article's Creative Commons licence and your intended use is not permitted by statutory regulation or exceeds the permitted use, you will need to obtain permission directly from the copyright holder. To view a copy of this licence, visit <http://creativecommons.org/licenses/by/4.0/>. The Creative Commons Public Domain Dedication waiver (<http://creativecommons.org/publicdomain/zero/1.0/>) applies to the data made available in this article, unless otherwise stated in a credit line to the data.