

Case Report: Spontaneous Renal Artery Pseudoaneurysm Treated by Arterial Embolization

Mohammed Habib ^{1*}, Majdy Ayyad ¹, Mohammed Balosha ²

¹ Cardiology Department- Alshifa Hospital- Gaza- Palestine, Israel.

² Radiology Department- Alshifa Hospital- Gaza- Palestine, Israel.

*Correspondence Author: Mohammed Habib, Cardiology Department-Alshifa Hospital- Gaza- Palestine, Israel

Received Date: September 09, 2022 | Accepted Date: September 16, 2022 | Published Date: September 26, 2022

Citation: Mohammed H, Majdy A, Mohammed B, (2022) Case Report: Spontaneous Renal Artery Pseudoaneurysm Treated by Arterial Embolization, Carcinogenesis and Chemotherapy, 1(1); Doi: 10.31579/cc-2022/001

Copyright: © 2022 Mohammed H. This is an open-access article distributed under the terms of The Creative Commons Attribution License, which permits unrestricted use, distribution, and reproduction in any medium, provided the original author and source are credited

Abstract

Renal artery pseudoaneurysm is a rare vascular lesion. It is found with increasing frequency as a result of unrelated abdominal imaging or on work-up for hypertension. The pseudoaneurysm can be defined as a pulsatile hematoma that communicates with the artery through a small hole in the arterial wall. However, the rupture of pseudoaneurysms is the most dreaded complication because it causes death. There are many causes of renal artery pseudoaneurysm and are generally related to renal biopsy, nephrectomy or percutaneous procedures. In addition, there is a relationship with penetrating traumas and, more rarely, with blunt traumas. We report a case of renal artery pseudoaneurysm treated successfully with vascular plug embolization. A 22-year-old woman with hypertension presented with an incidental left renal artery pseudoaneurysm measuring 35x23 mm. We successfully performed endovascular treatment with vascular plug embolization without any complications.

Keywords: renal artery pseudoaneurysms; vascular plug embolization

Introduction

Renal arterial pseudoaneurysm is a haematoma contained by the surrounding structures outside the vessel wall. (1) The incidence is low, the overall incidence ranges between 0.01% and 1% (2). This increases to 2.5% when only patients with systemic hypertension are considered (3).

The renal artery pseudoaneurysm etiologically are associated with intervention procedures such as partial nephrectomy, percutaneous procedures, renal biopsy. But can be related to penetrating trauma and more rarely blunt trauma. (4-5). Although it may be spontaneous as described in this case without history of trauma, renal surgery, percutaneous procedures, as well as inflammatory and neoplastic processes within the kidney.

Case report

A 22-year-old woman visited the cardiology department with headache and systemic hypertension abdominal pain and bloody stool. She had been taking antihypertensive medicine for 2 years, and her blood pressure was well

uncontrolled. On admission, her vital signs were as follows: blood pressure, 178/110 mmHg; heart rate 78 bpm; respiratory rate, 20 bpm; and body temperature, 37.5 and physical examination did not reveal any abnormalities. Her complete blood count revealed the following: hemoglobin level, 11.9 g/dL; white blood cell count, 6,580/mm³; and platelet count, 218,000/mm³. A basic metabolic panel revealed no abnormalities; her creatinine level was 0.97 mg/dL. She take valsartan/hydrochlorothiazide (160/25)mg tablet and 5 mg bisoprolol medication to control high blood pressure She was not any past medical histories including trauma, renal surgery, percutaneous procedures, as well as inflammatory and neoplastic processes within the kidney.

Her abdominal CT angiography revealed a 2.3x3.5 cm sized left renal artery saccular pseudoaneurysm. A left renal artery pseudoaneurysm was observed near the proximal part of the inferior branch on the angiogram.

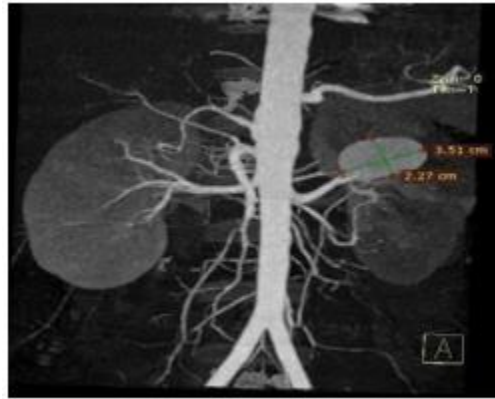


Figure 1: CT angiography revealed an 2.3x3.5 cm sized left renal artery saccular pseudoaneurysm

Selective left renal angiography was done and suggested pseudoaneurysm at the proximal inferior branch of the left renal artery. We inserted a vascular plug 6x7 mm and deployed at the proximal inferior branch of the left renal artery (Figure. 2,3). There were no complications of endovascular treatment.

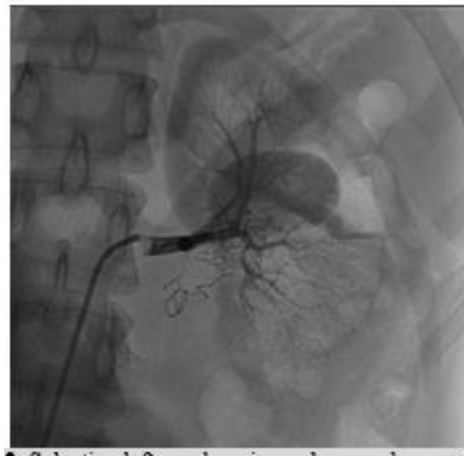

Figure 2: Selective left renal angiography was done and suggested pseudoaneurysm at the proximal inferior branch of the Left renal artery

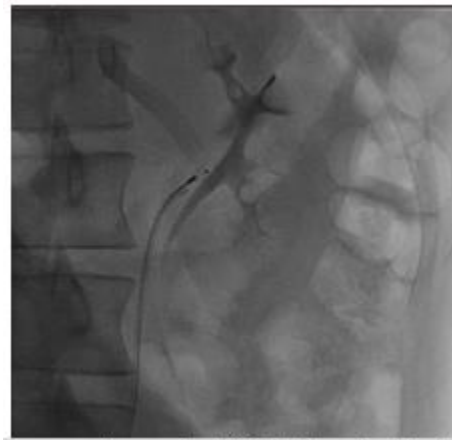


Figure 3: vascular plug deployment at the neck of pseudoaneurysm

Discussion

embolization (coils, gelfom or alcohol) or stenting across the aneurysm is. The incidence of renal artery pseudoaneurysm in patient with hypertension unresponsive to medical therapy can be as high as 39% (6) the etiologies of pseudoaneurysm are long standing untreated hypertension, surgical manipulation (open, laparoscopic, and/or endovascular) blunt and penetrating trauma, infectious angiomyolipomas (i.e., mycotic), polyarteritis nodosa, malignancy, radiation, and/or cyclophosphamide use (7,8). The risk of rupture is thought to vary inversely with size, and most investigators agree that an aneurysm exceeding 2 cm is more likely to undergo rupture and

interventions are indicated in pseudoaneurysms greater than 2 cm, or when associated with complications such as severe hemorrhage and renovascular hypertension. (9) Indications for treatment include uncontrolled hypertension, progressive enlargement, with size >2 to 2.5 cm or size >1 cm in a female of childbearing age (10). Currently, endovascular treatments include the intervention of choice in elective circumstances (11).

Conclusion

We report a case of left renal artery pseudoaneurysm with severe uncontrolled systemic hypertension in a young female who did not control

high blood pressure for a 2 years was treated successfully of vascular plug system. To the best of our knowledge this is the first report of a spontaneous renal artery pseudoaneurysm with no predisposing factors and was managed by selective arteriography and embolisation using vascular plug.

References

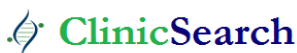1. Arteché AH, Roman CA, Toro RM, Gomez PPA, González FS, (2014). Pseudoaneurisma de artéria renal principal associada a fistula cecal trasnephrectomia radical: caso clínico y revisión de la literatura. *Sanid Mil*; 70:95-97.
2. Annopoulos A, Manousakas T, Alexopoulou E, Brountzos E, Papadoukakis S, et al (2004) Delayed life-threatening haematuria from a renal pseudoaneurysm caused by blunt renal trauma treated with selective embolization. *Urol Int.*; 72:352–354.
3. Porcaro AB, Migliorini F, Pianon R, Antonioli SZ, Furlan F, et al. (2004). Intraparenchymal renal artery aneurysms: case report with review and update of the literature. *Int Urol Nephrol.*; 36:409–416.
4. Castillo CO, Díaz MJ, Caffarena AE, Díaz CM, Hoyos MJ. (2006). Pseudoaneurisma arteria renal postnephrectomía parcial: Tratamiento exitoso con embolización selectiva. *Rev Chil Cir*; 58:382-325.
5. Melo RAV, Pires MJM, Silva LMS, Segóvia AB. (2013). Giant renal artery pseudoaneurysm 18 months after blunt trauma. *J Vasc Bras*; 12:159-162.
6. De Wilde V, Devue K, Vandembroucke F, Breucq C, De Maeseneer M, et al (2007) Rupture of renal artery aneurysm into the renal pelvis,

Ready to submit your research? Choose ClinicSearch and benefit from:

- fast, convenient online submission
- rigorous peer review by experienced research in your field
- rapid publication on acceptance
- authors retain copyrights
- unique DOI for all articles
- immediate, unrestricted online access

At ClinicSearch, research is always in progress.

Learn more <https://clinicsearchonline.org/journals/carcinogenesis-and-chemotherapy>



© The Author(s) 2022. **Open Access** This article is licensed under a Creative Commons Attribution 4.0 International License, which permits use, sharing, adaptation, distribution and reproduction in any medium or format, as long as you give appropriate credit to the original author(s) and the source, provide a link to the Creative Commons licence, and indicate if changes were made. The images or other third party material in this article are included in the article's Creative Commons licence, unless indicated otherwise in a credit line to the material. If material is not included in the article's Creative Commons licence and your intended use is not permitted by statutory regulation or exceeds the permitted use, you will need to obtain permission directly from the copyright holder. To view a copy of this licence, visit <http://creativecommons.org/licenses/by/4.0/>. The Creative Commons Public Domain Dedication waiver (<http://creativecommons.org/publicdomain/zero/1.0/>) applies to the data made available in this article, unless otherwise stated in a credit line to the data.